

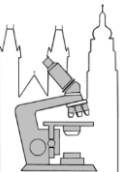# Případ SD-IAP 792

**Aleš Ryška**

Fingerlandův ústav patologie

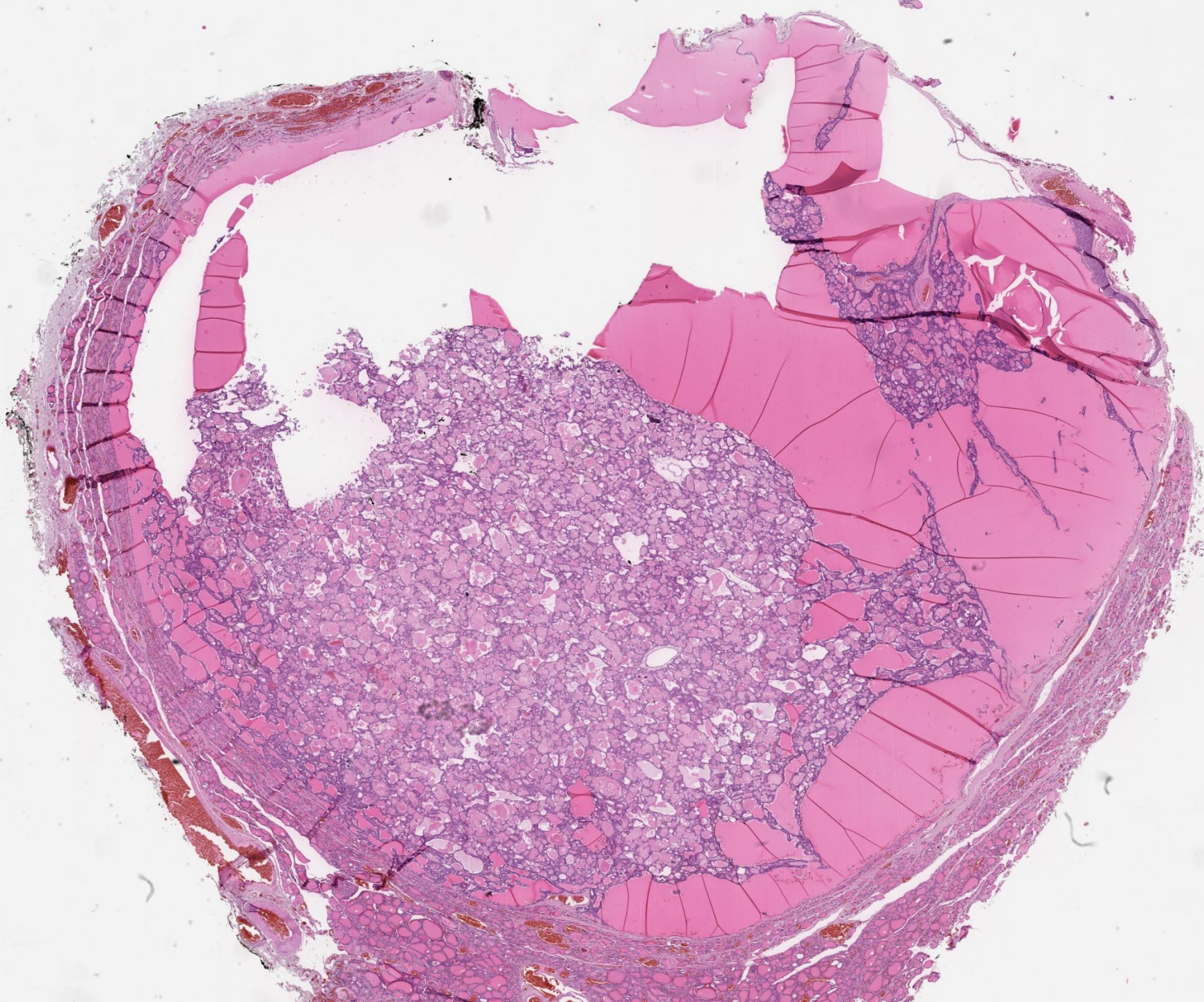
LF UK a FNHK

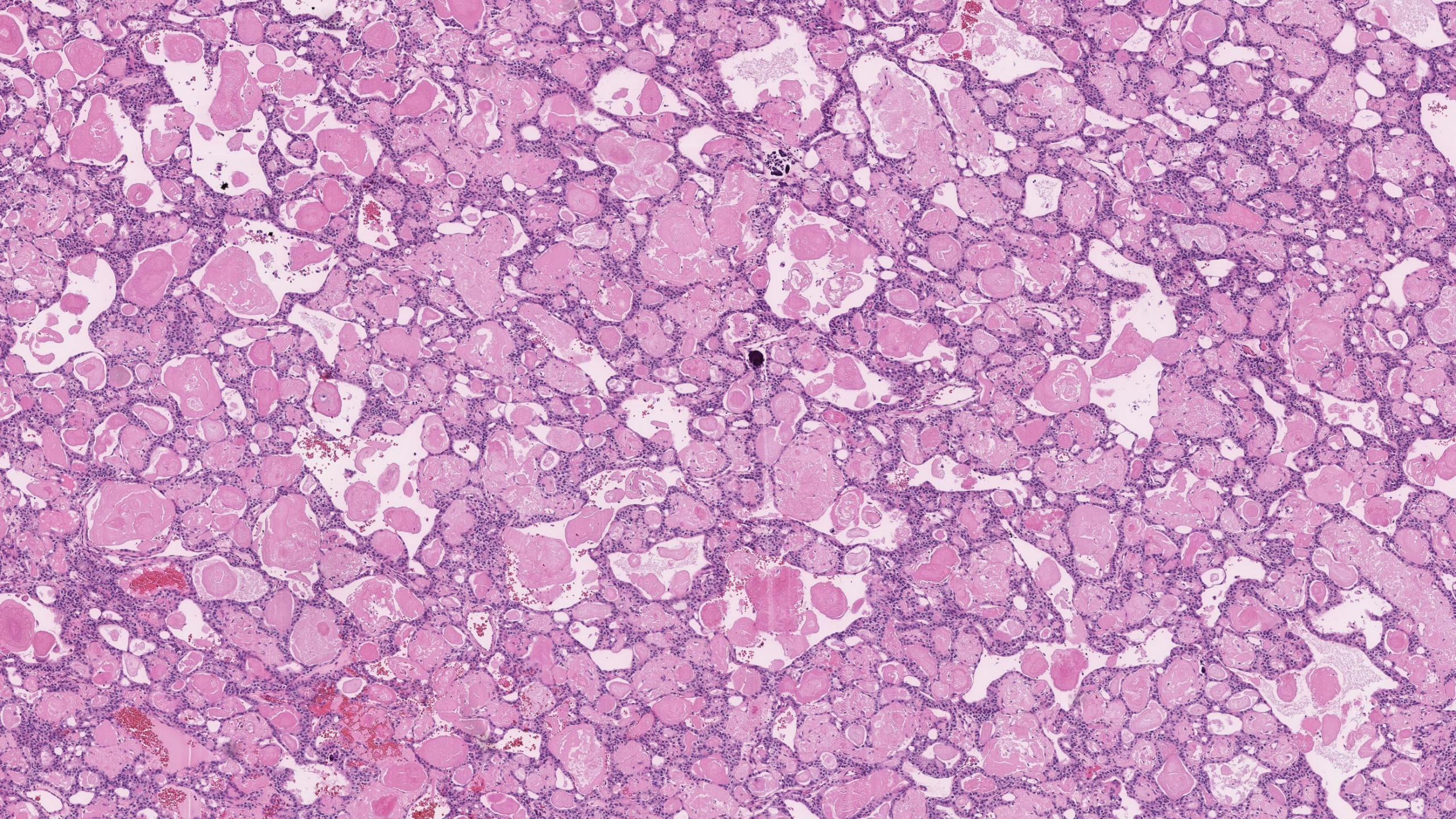
Hradec Králové

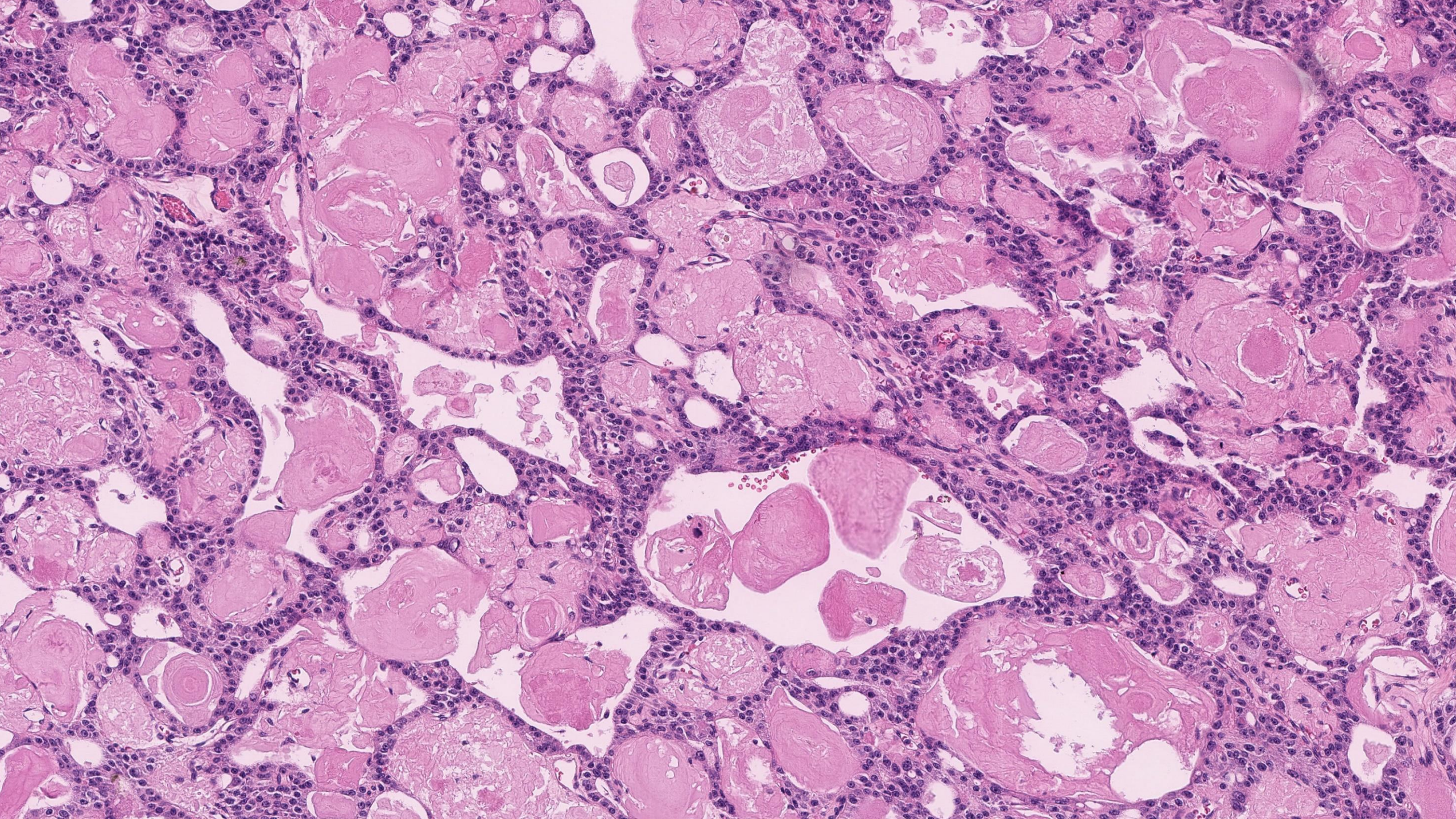


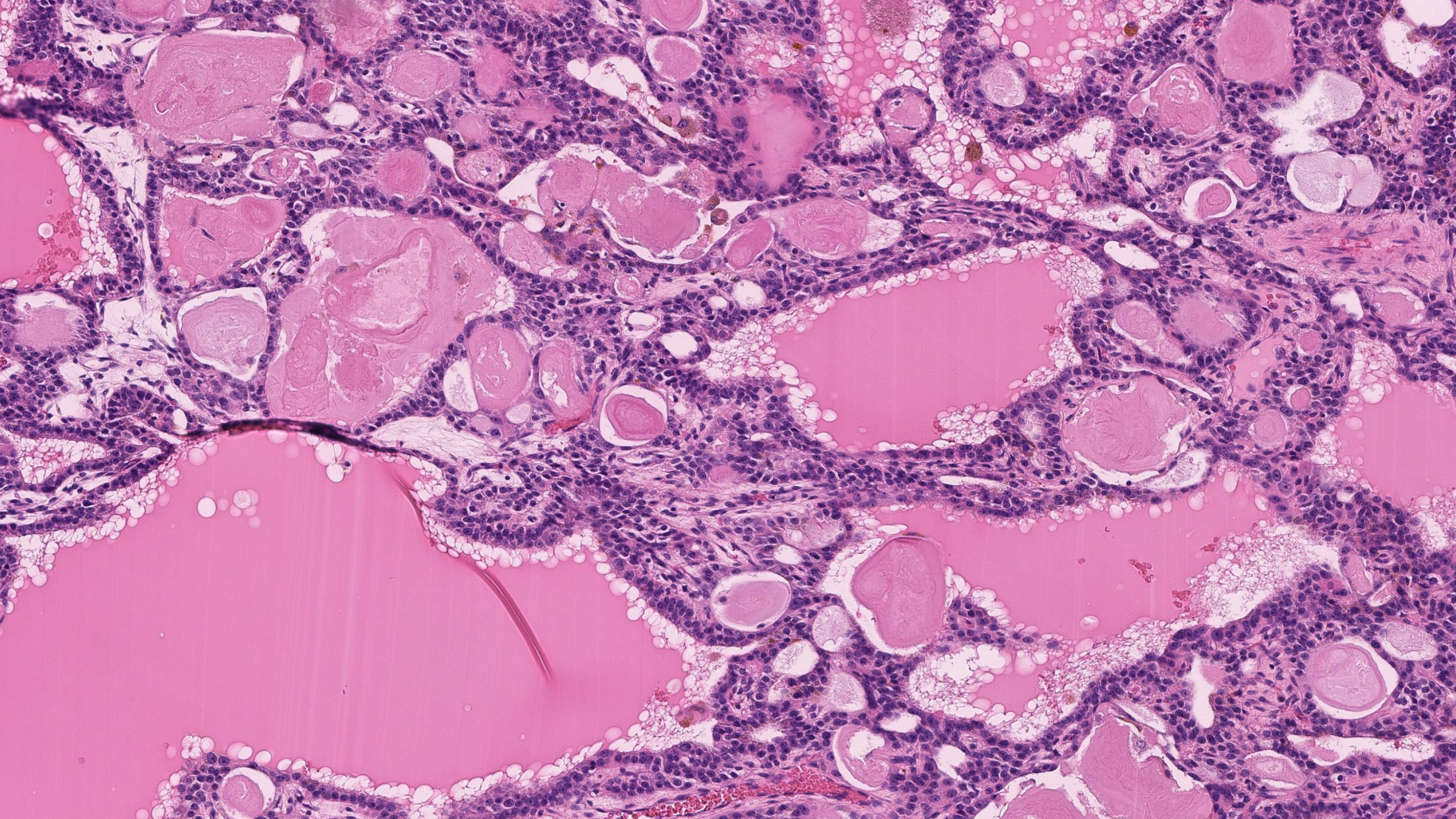
# Klinická data

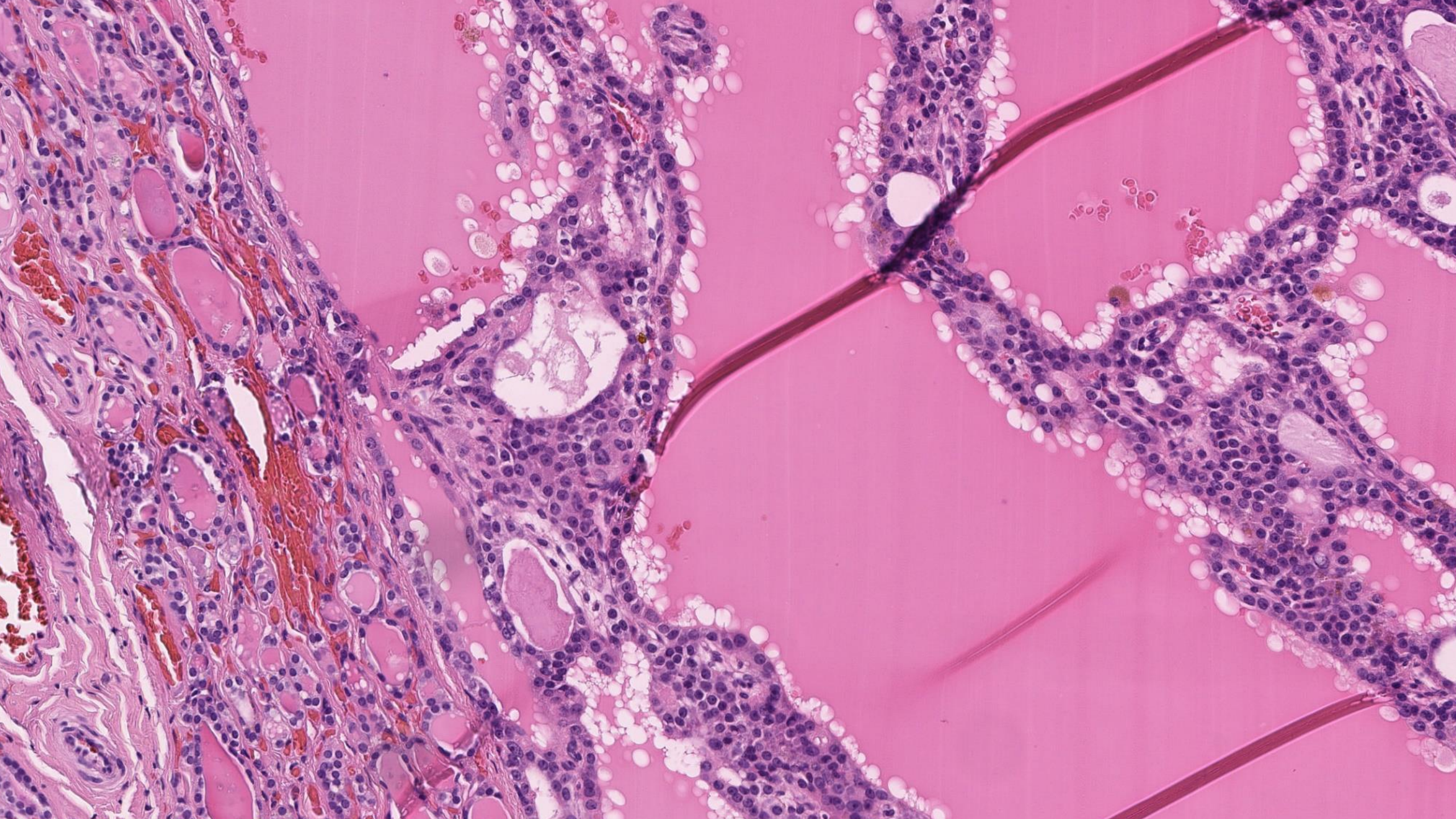
- Ž, 63 r., pravý lalok štítné žlázy
- Dg. E041 – struma nodosa
  
- Lalok 45x26x18mm, hrboľatý povrch
- Na řezu ohraničený uzel prům. 20 mm, zčásti bělavý
- Ostatní tkáň homogenní, hnědé barvy

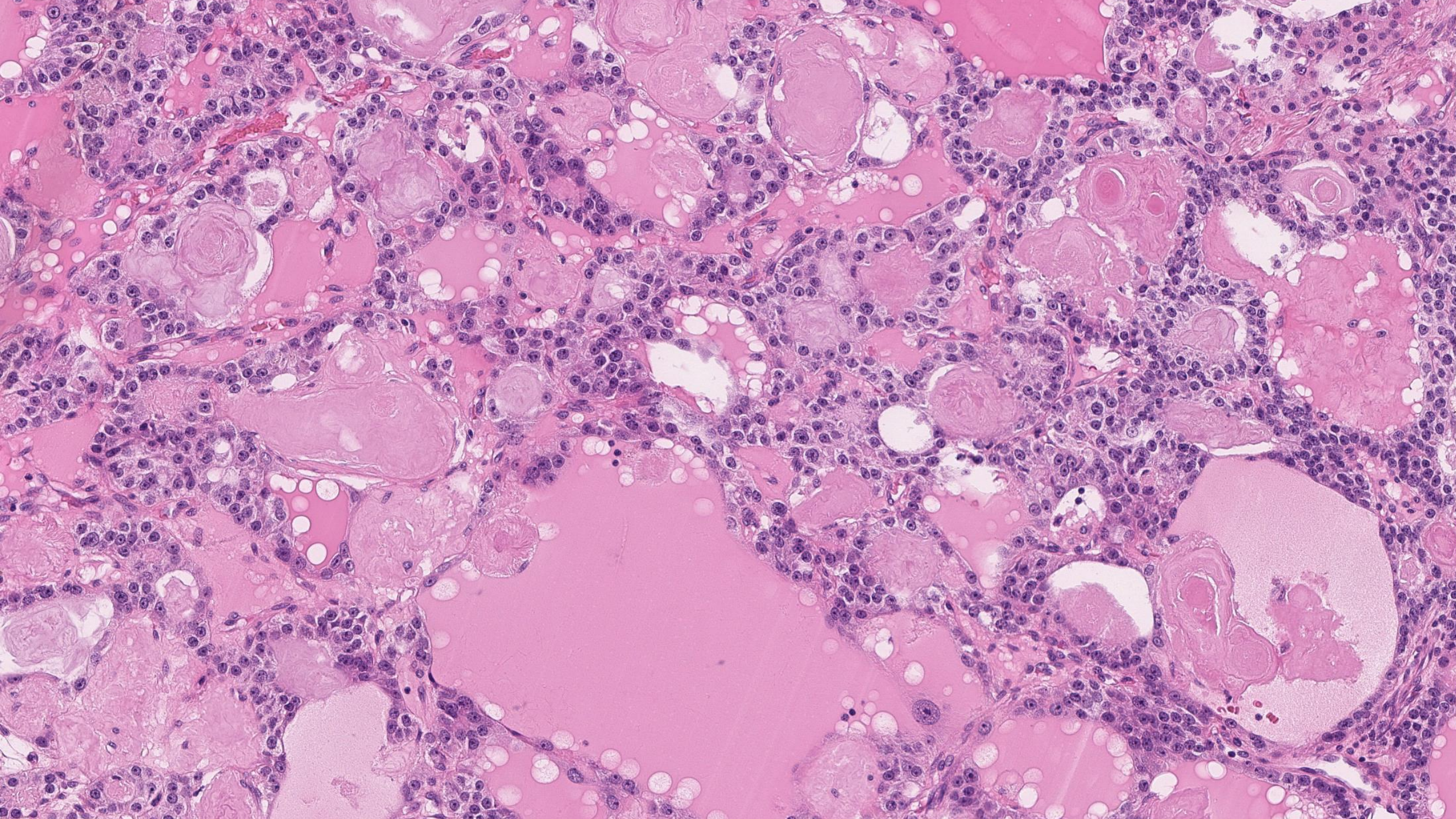




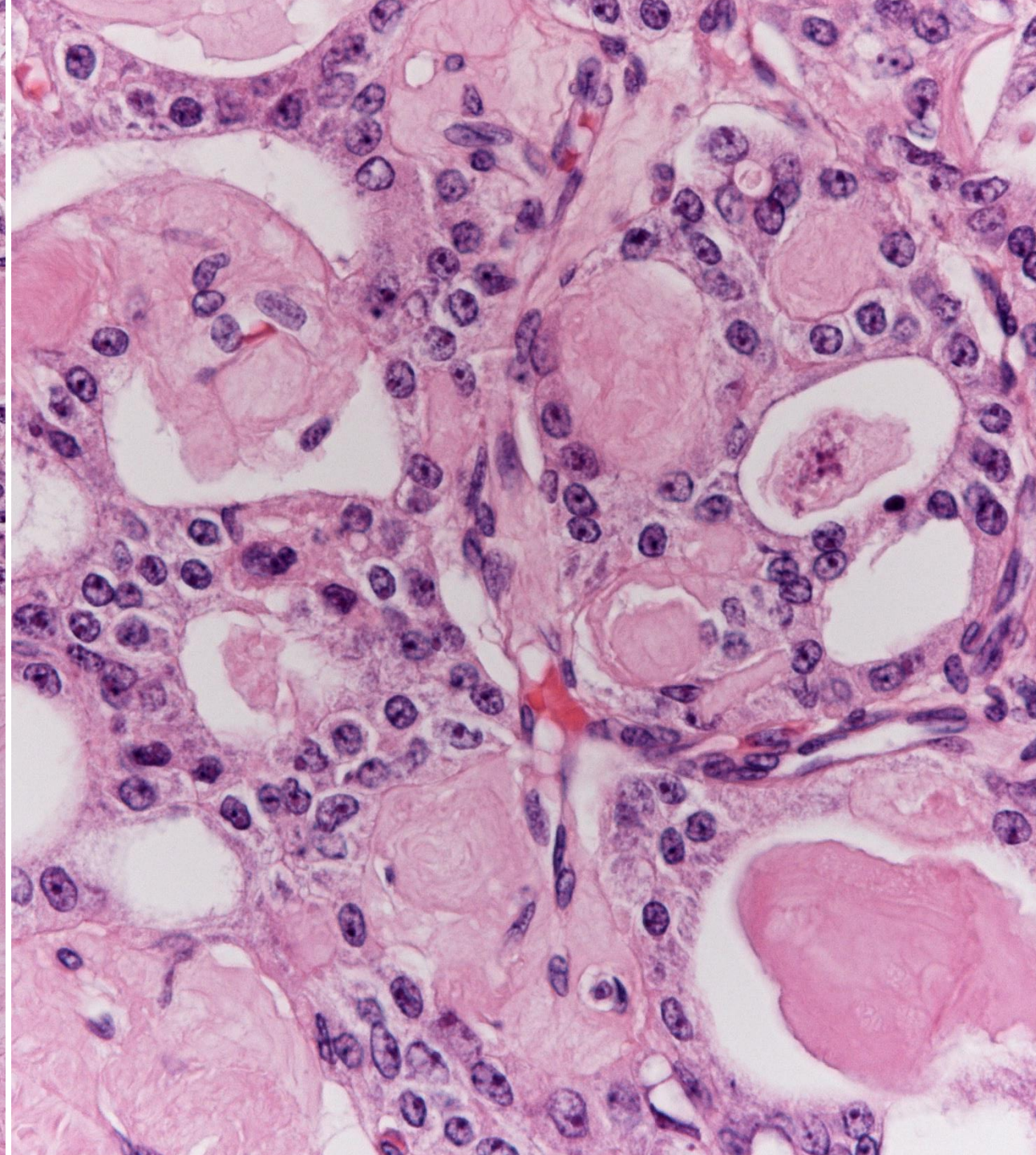
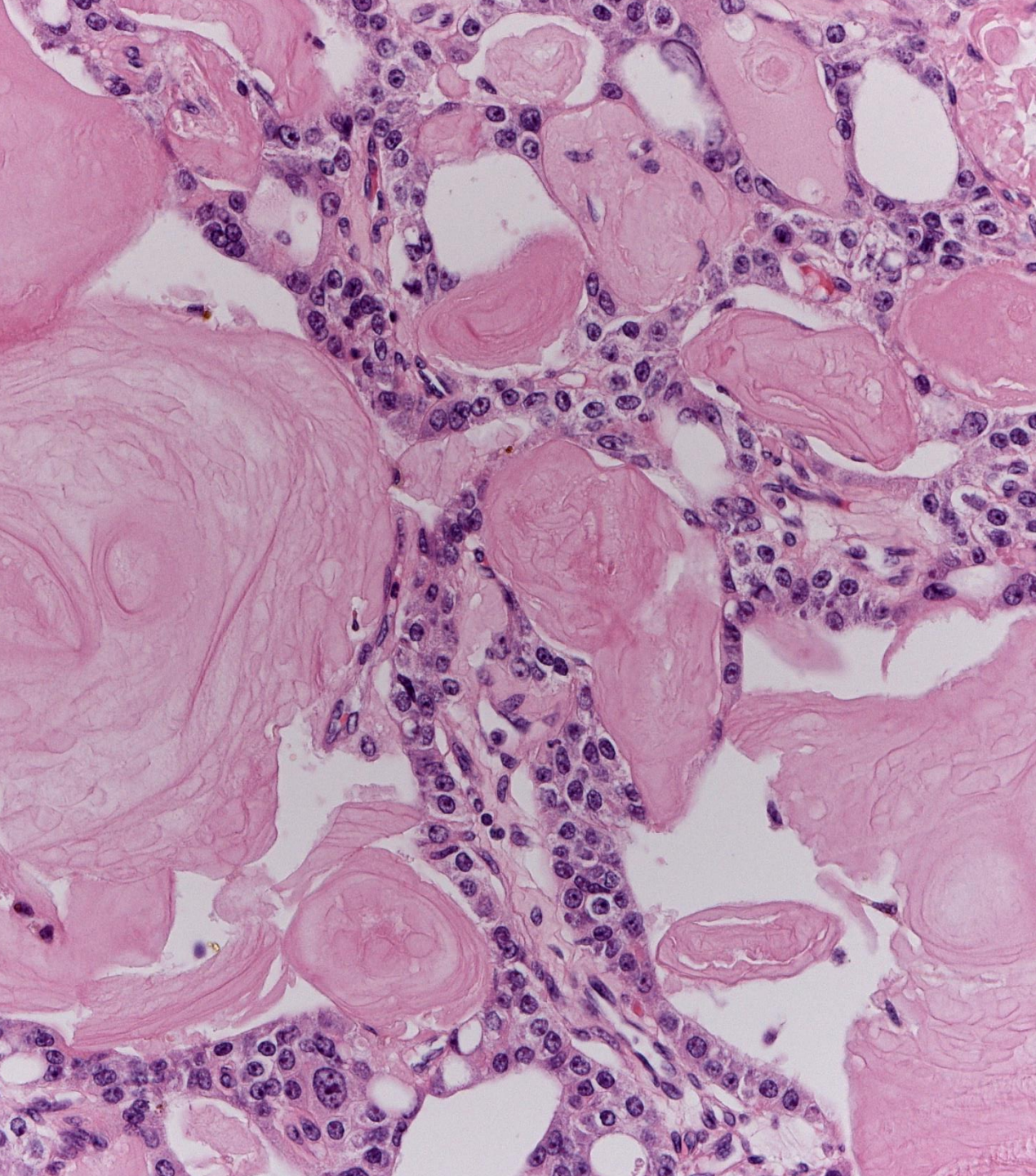











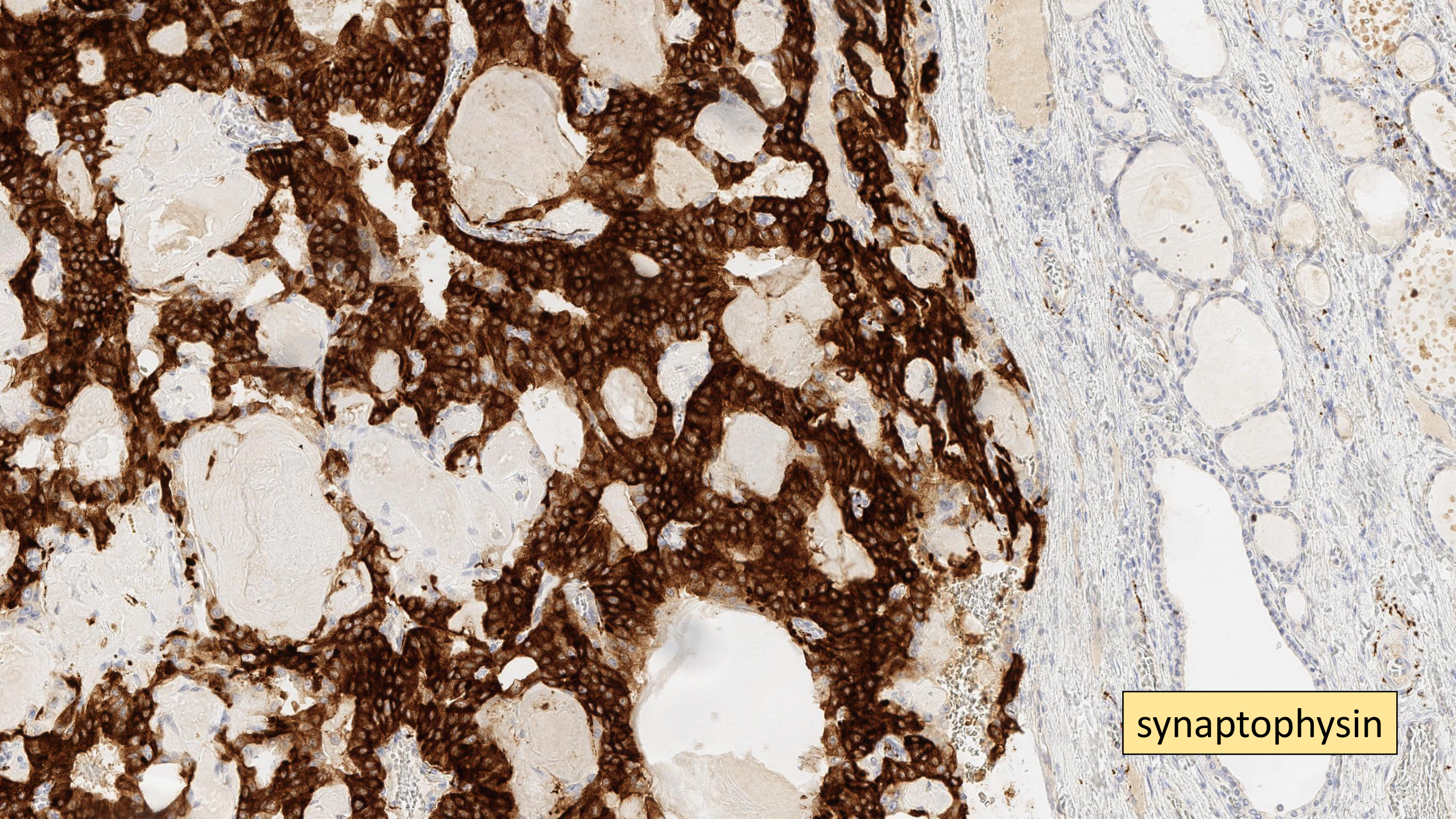


Vnitřní požadavek		Příjmení pacienta	Číslo biopsie
(5) kalzit Syu kongo maldivy			B13717/22
		STATIM	KONZULTACE
			X
		POZNÁMKA (DODATEK)	
		Záznamy administrativy, kódy	
		231-4 ✓ 223-2x ✓	
Datum	Podpis		
20.7.			
Záznamy laboratoře - datum, zadání, podpis			
20.7. 210K			

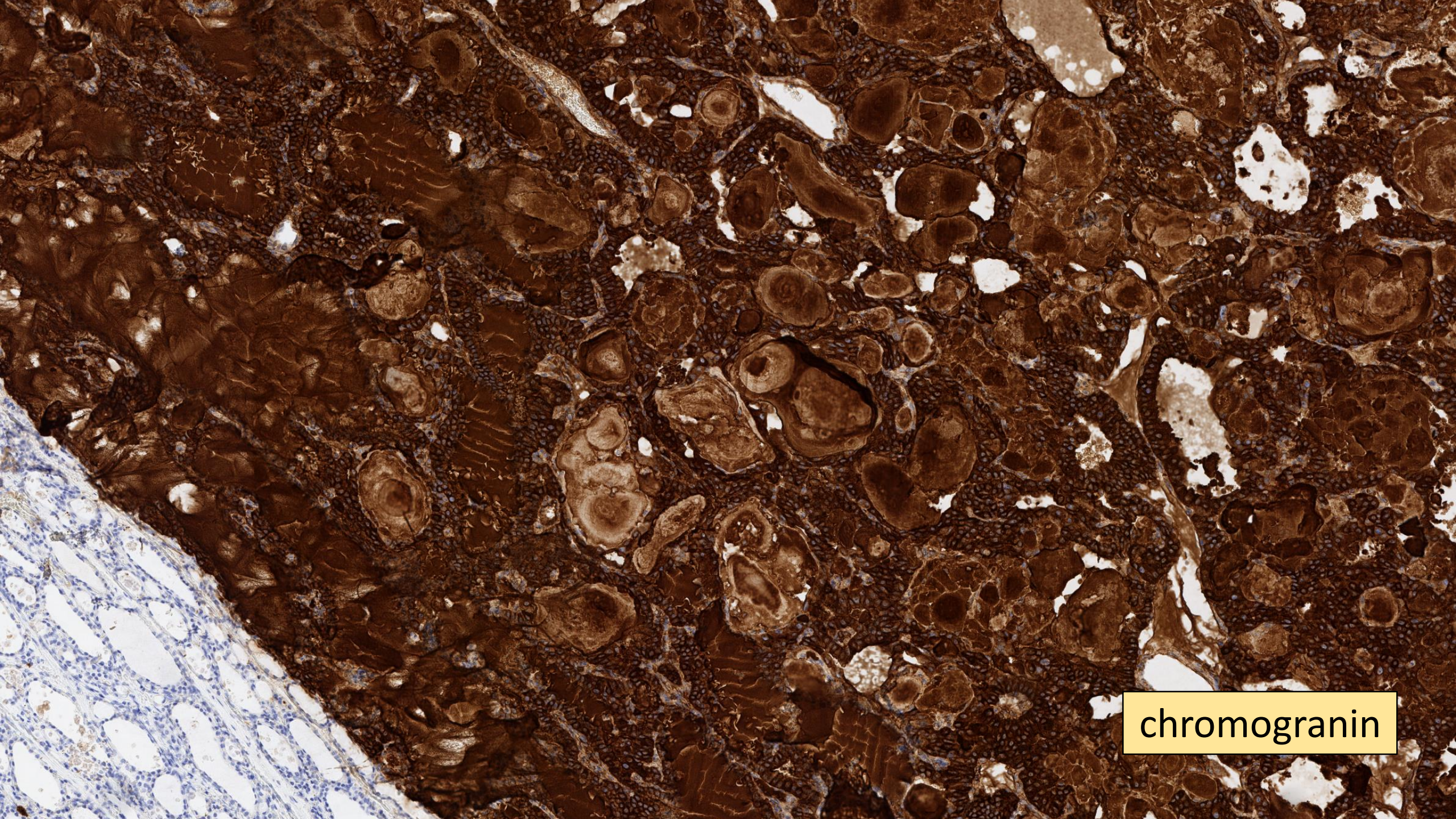
28.7.2022

B-13717/2022-2

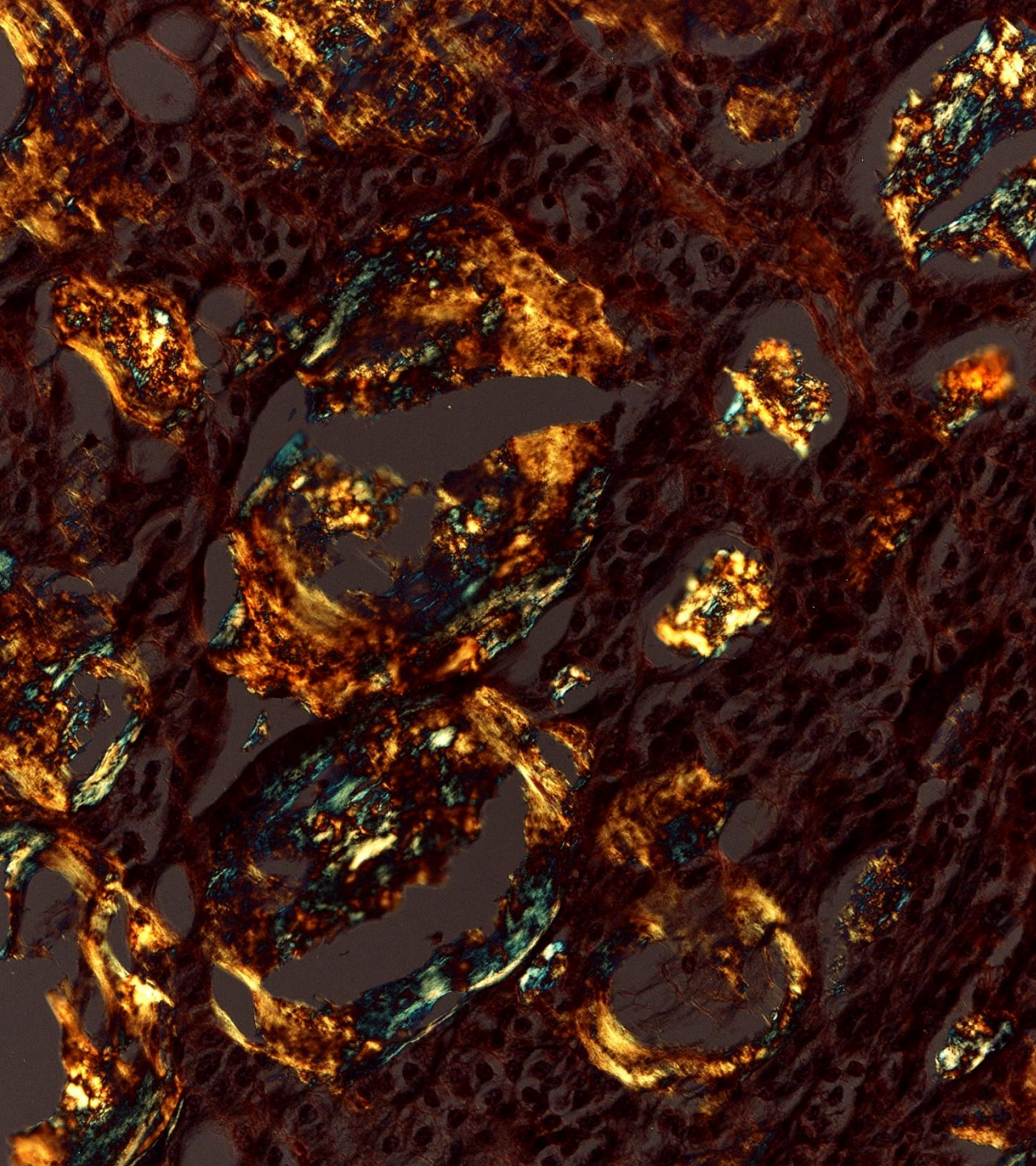
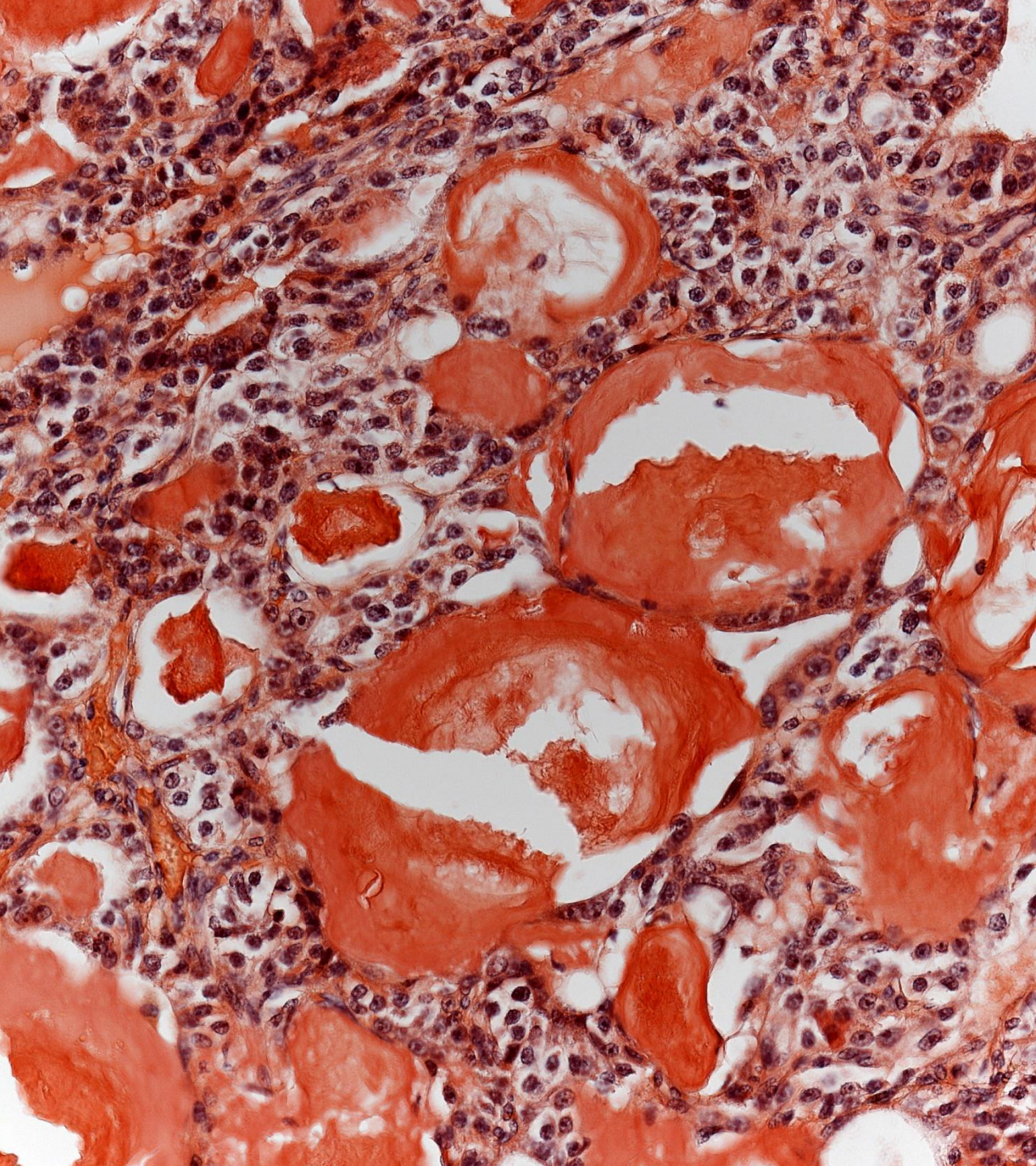


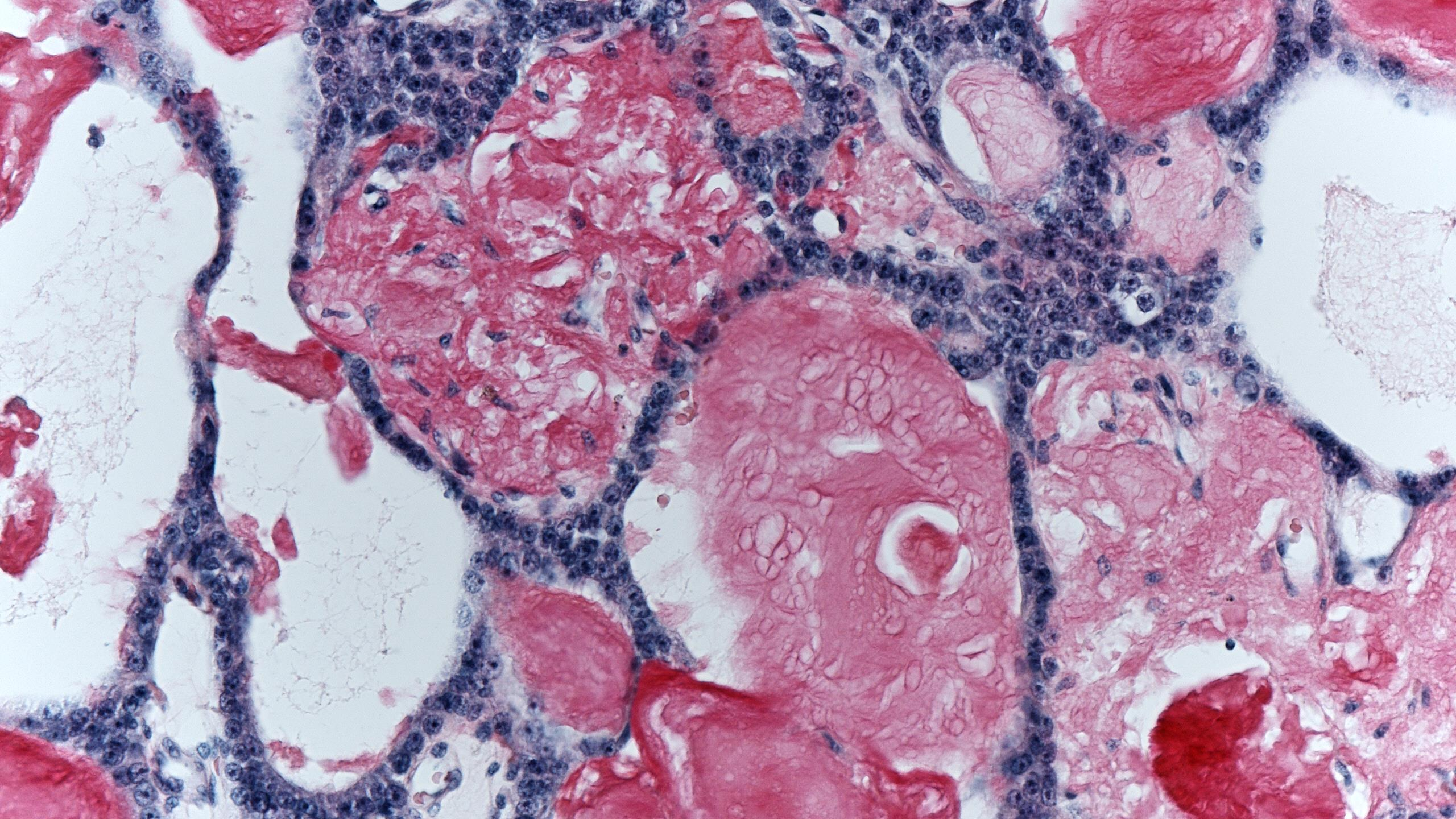


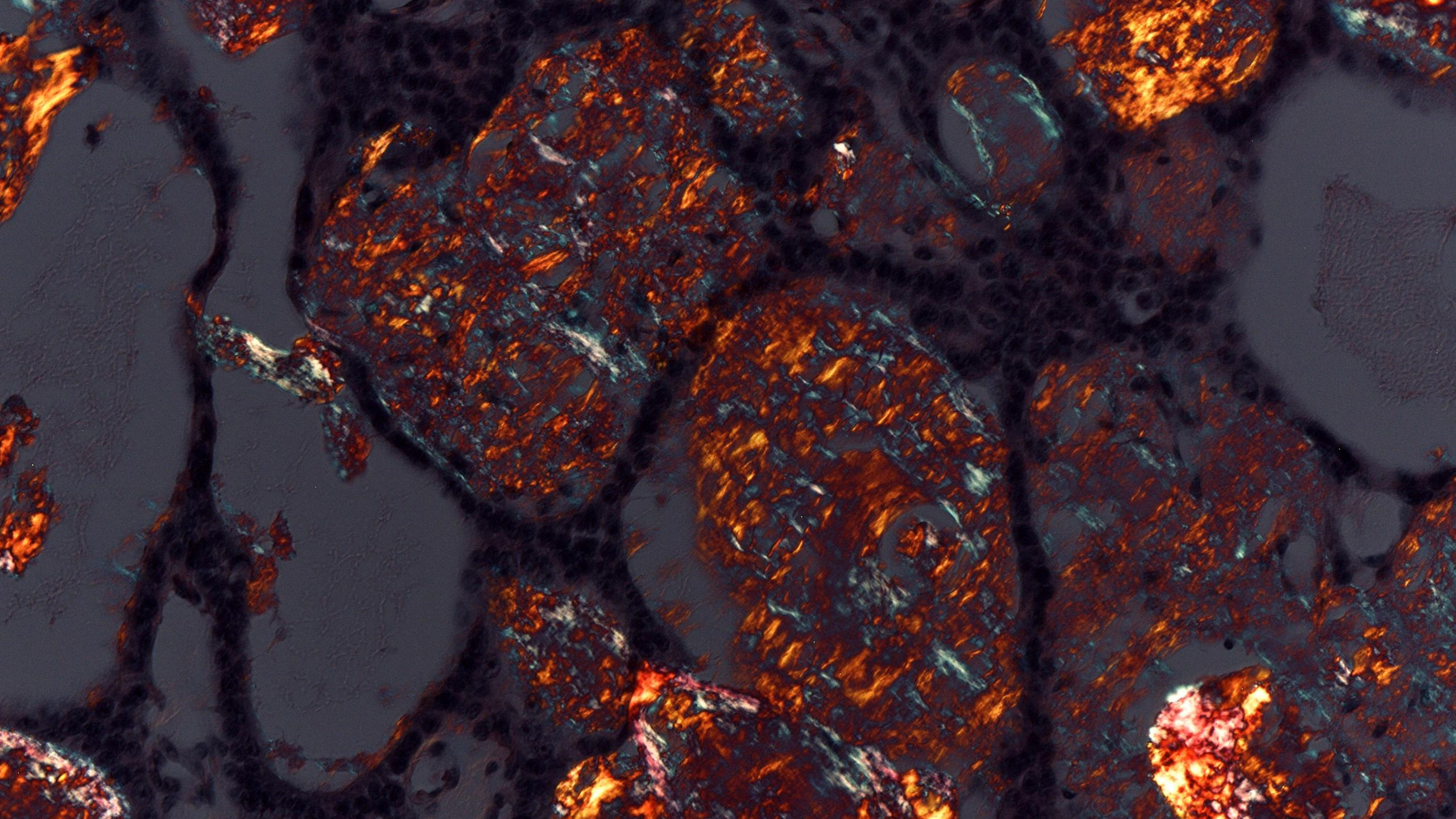
synaptophysin



chromogranin







?

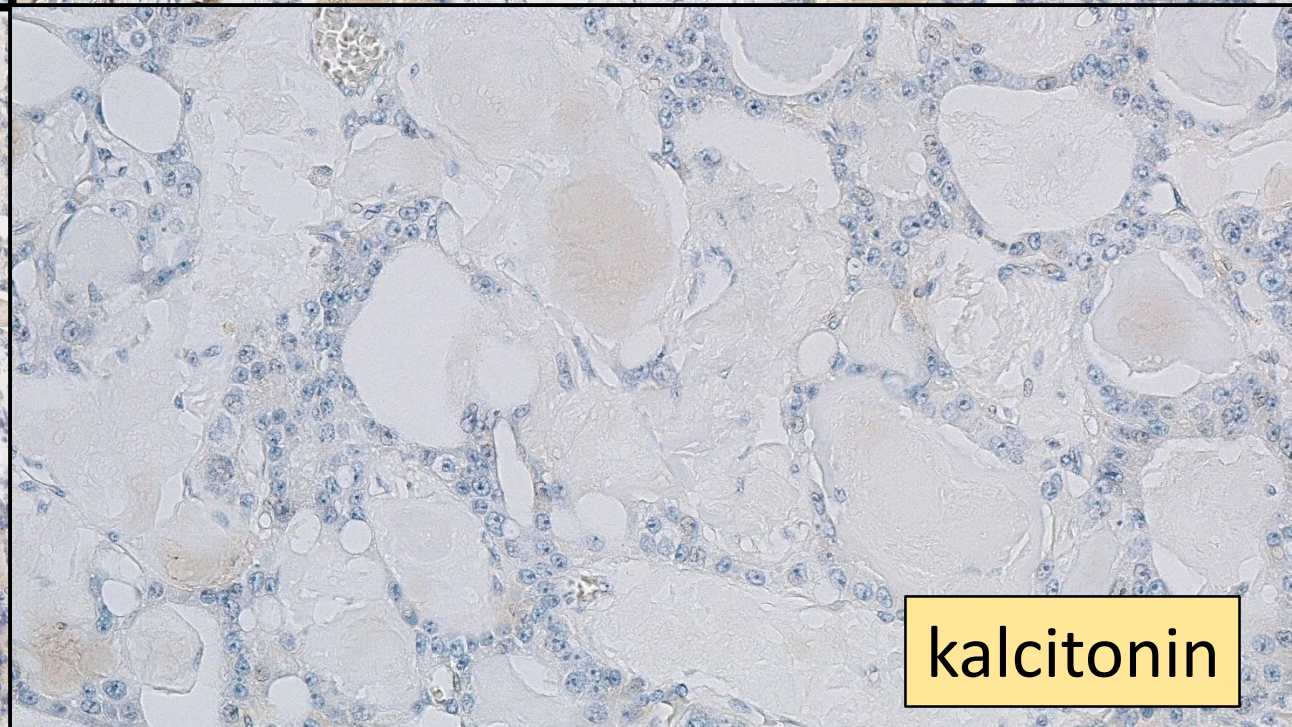
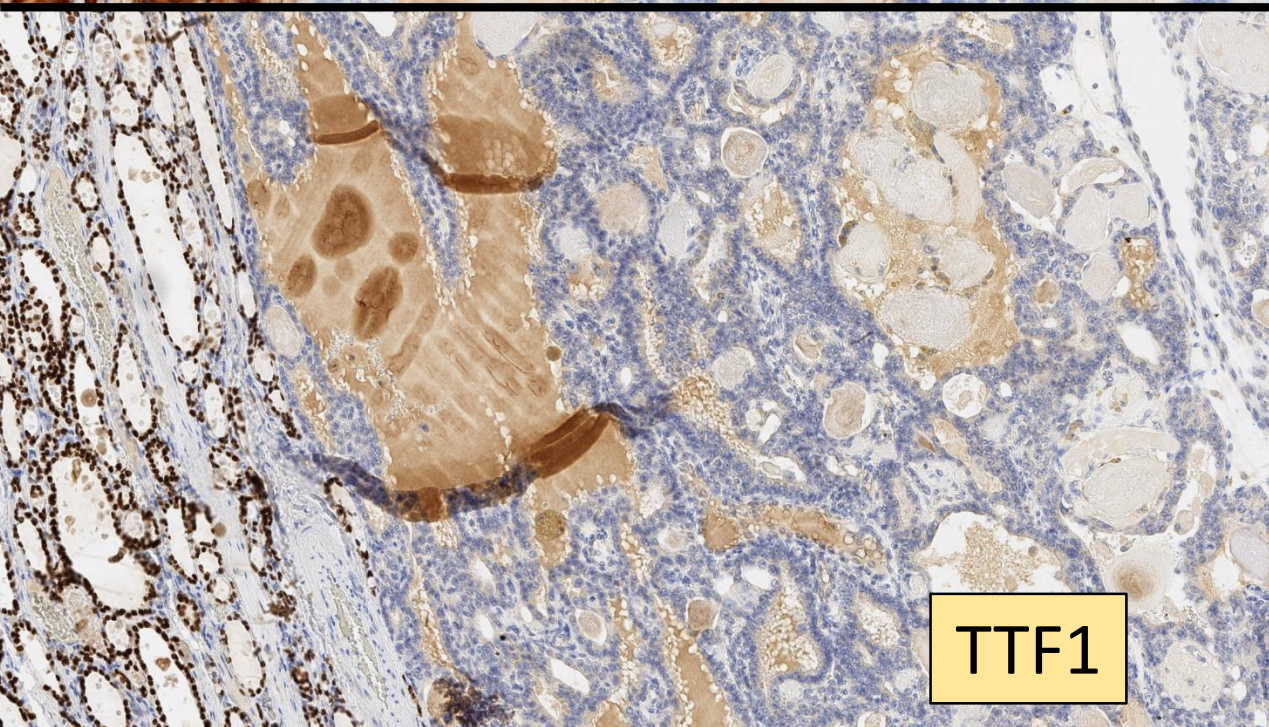
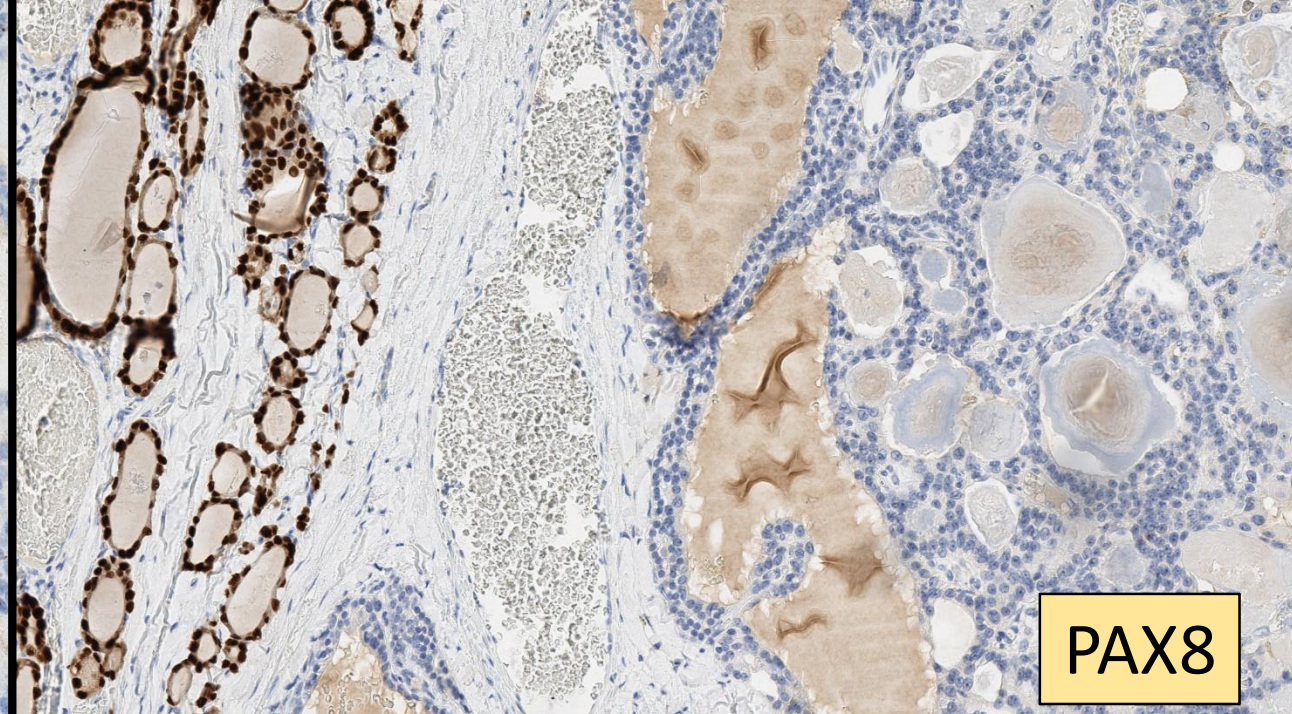
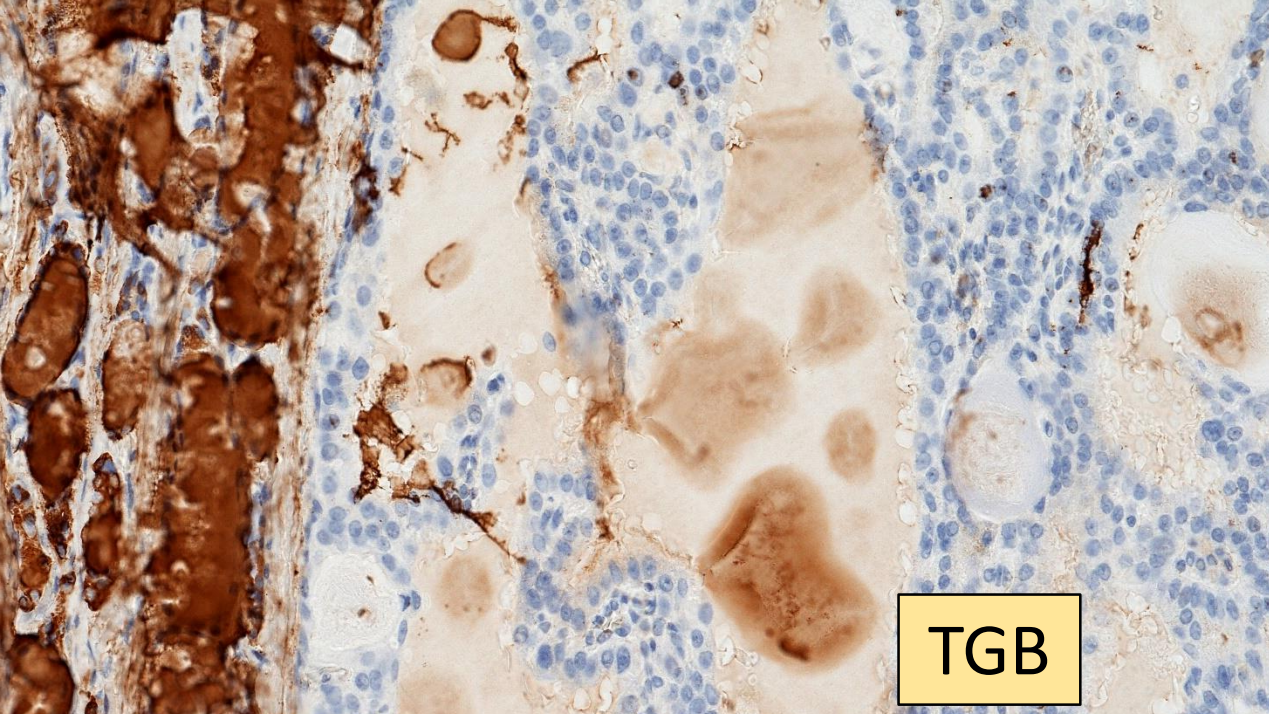


Vnitřní požadavek		Příjmení pacienta		Číslo biopsie
<p>(4) PAX 8 TGL TTF1 kalcit chrg</p> <p>(6) kalcit</p> <p><i>[Signature]</i></p>				B13717/22
		STATIM	KONZULTACE	POZNÁMKA (DODATEK)
			X	
Záznamy administrativy, kódy				
<p><i>st 231-111</i></p>				
Datum		Podpis		
15.7.		<i>[Signature]</i>		
Záznamy laboratoře - datum, zadání, podpis				
18.7 e600				



28.7.2022

B-13717/2022-4





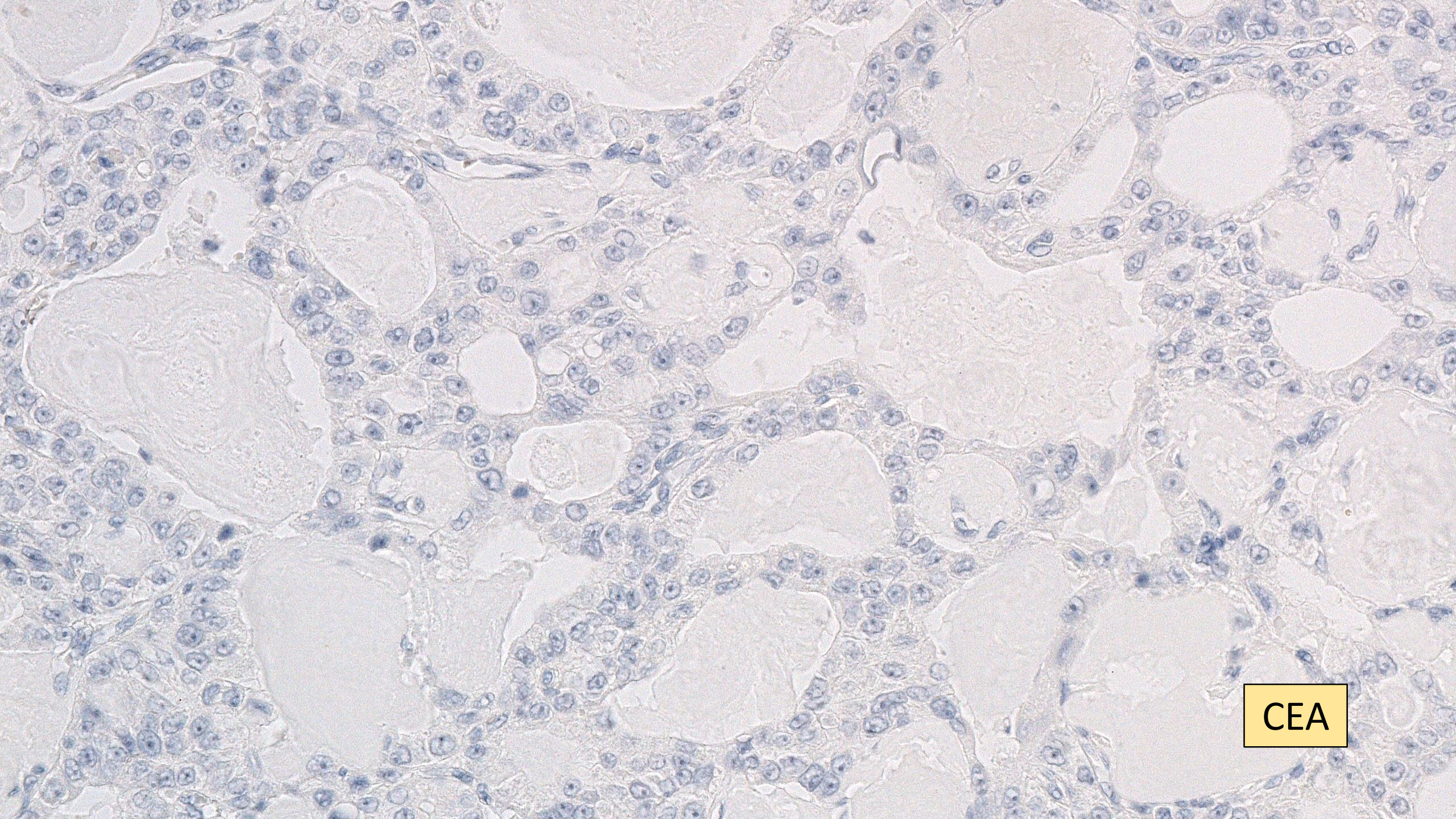
?

Vnitřní požadavek		Příjmení pacienta	Číslo biopsie	
(5) Ki67 CEA  			B13717/22	
		STATIM	KONZULTACE	POZNÁMKA (DODATEK)
		Záznamy administrativy, kódy		
		84231-4x ✓		
Datum	Podpis			
22.7.				
Záznamy laboratoře - datum, zadání, podpis				
24.7.22 R 17-00				

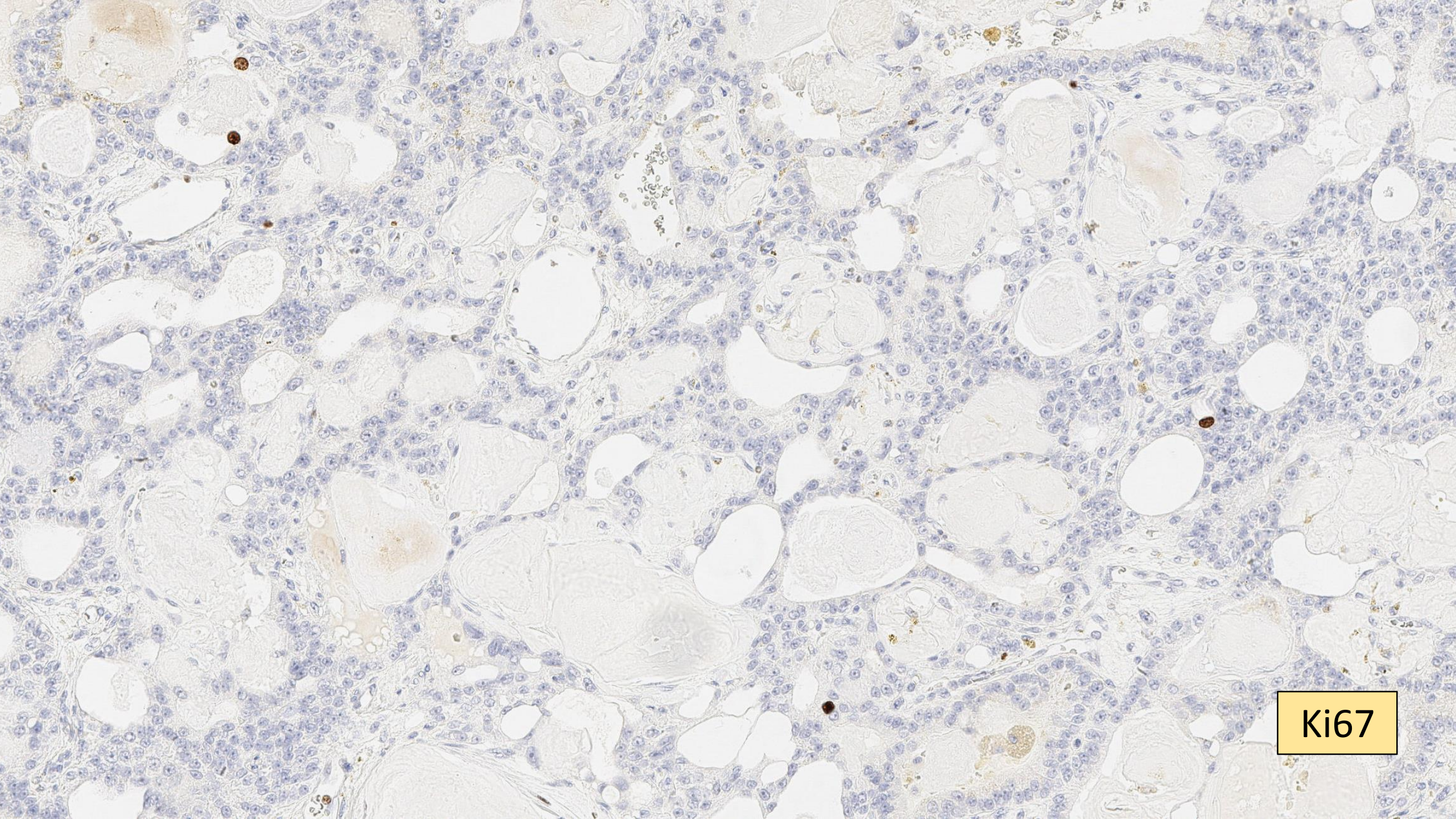
28.7.2022

B-13717/2022-3





CEA



Ki67



THOMAS

הודעת קול  
הודעת טקסט  
הודעת וידאו

Gigaset  
DL380

A

B

C

D

1

2 ABC

3 DEF

4 GHI

5 JKL

6 MNO

7 PQRS

8 TUV

9 WXYZ

\* Δ

0 L

#

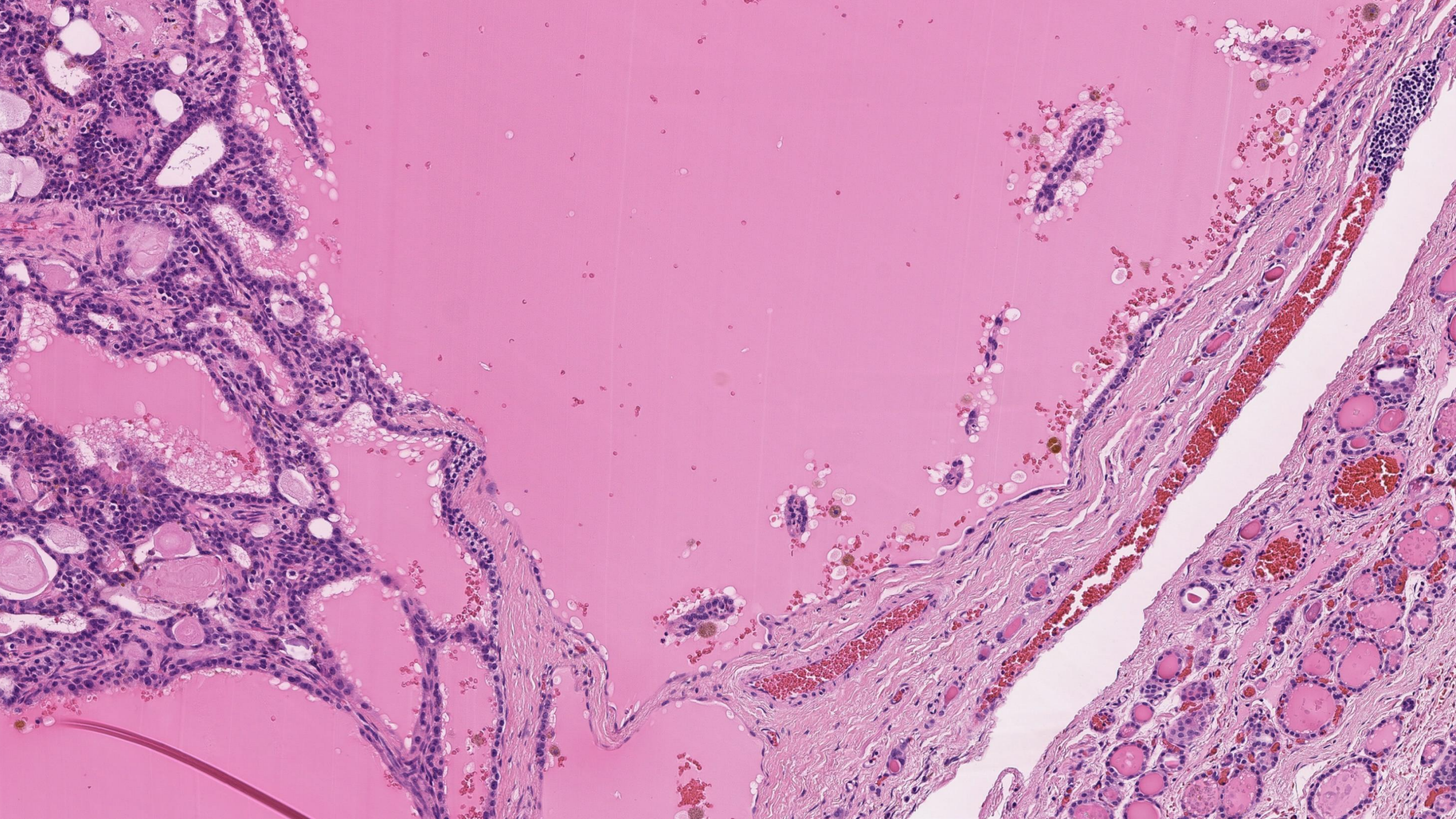
OK MENU

←

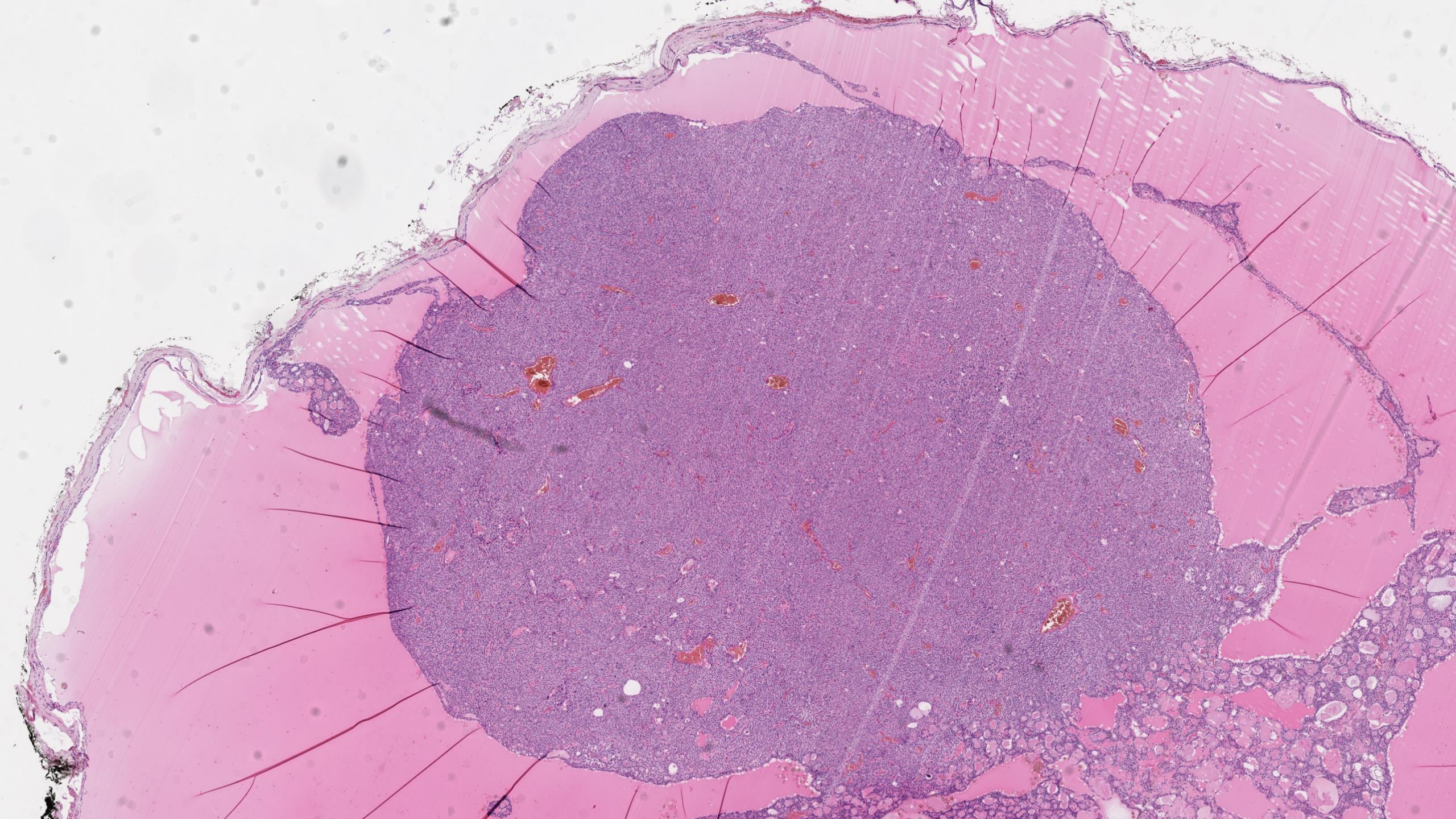
R

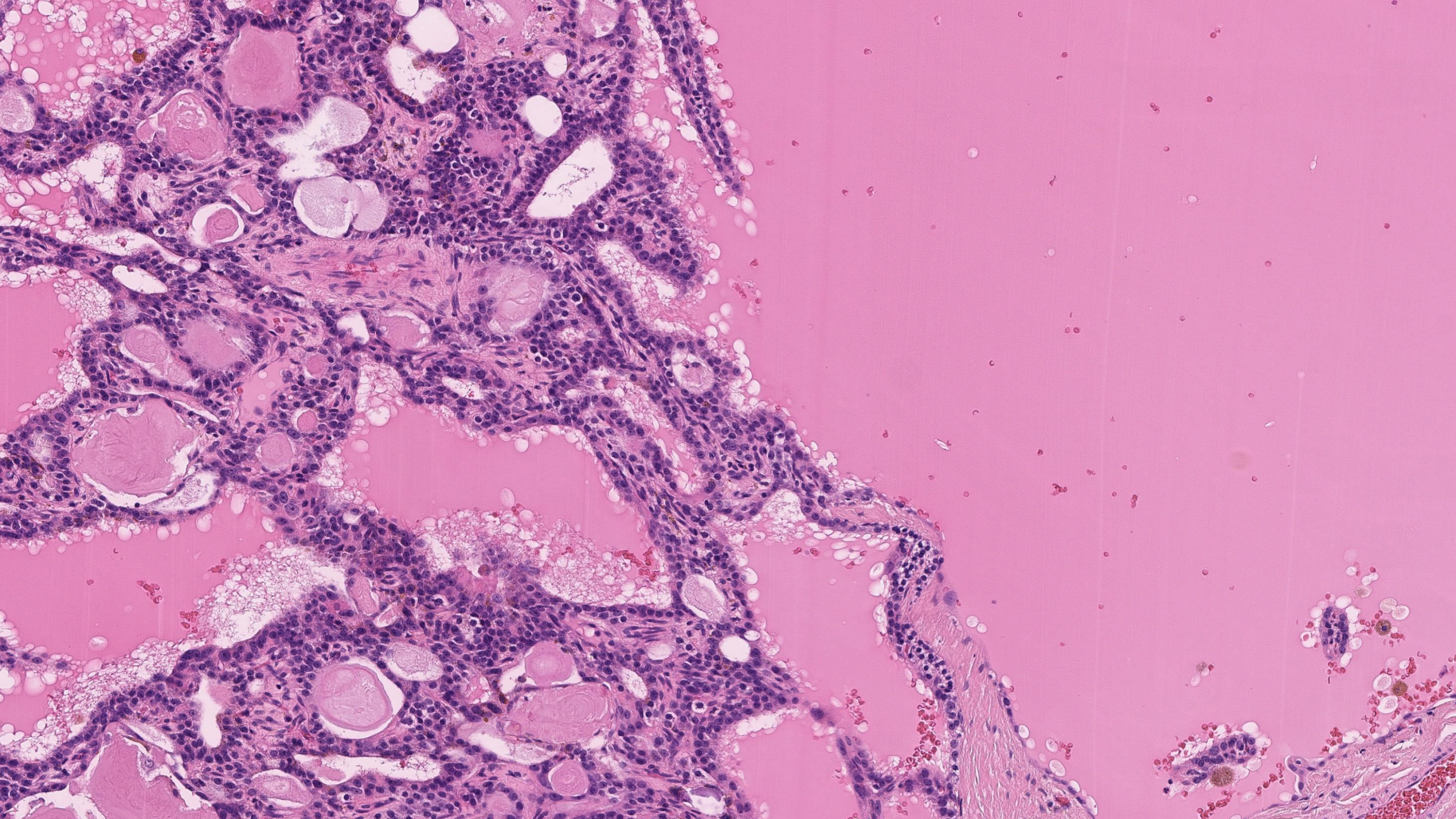
⊞

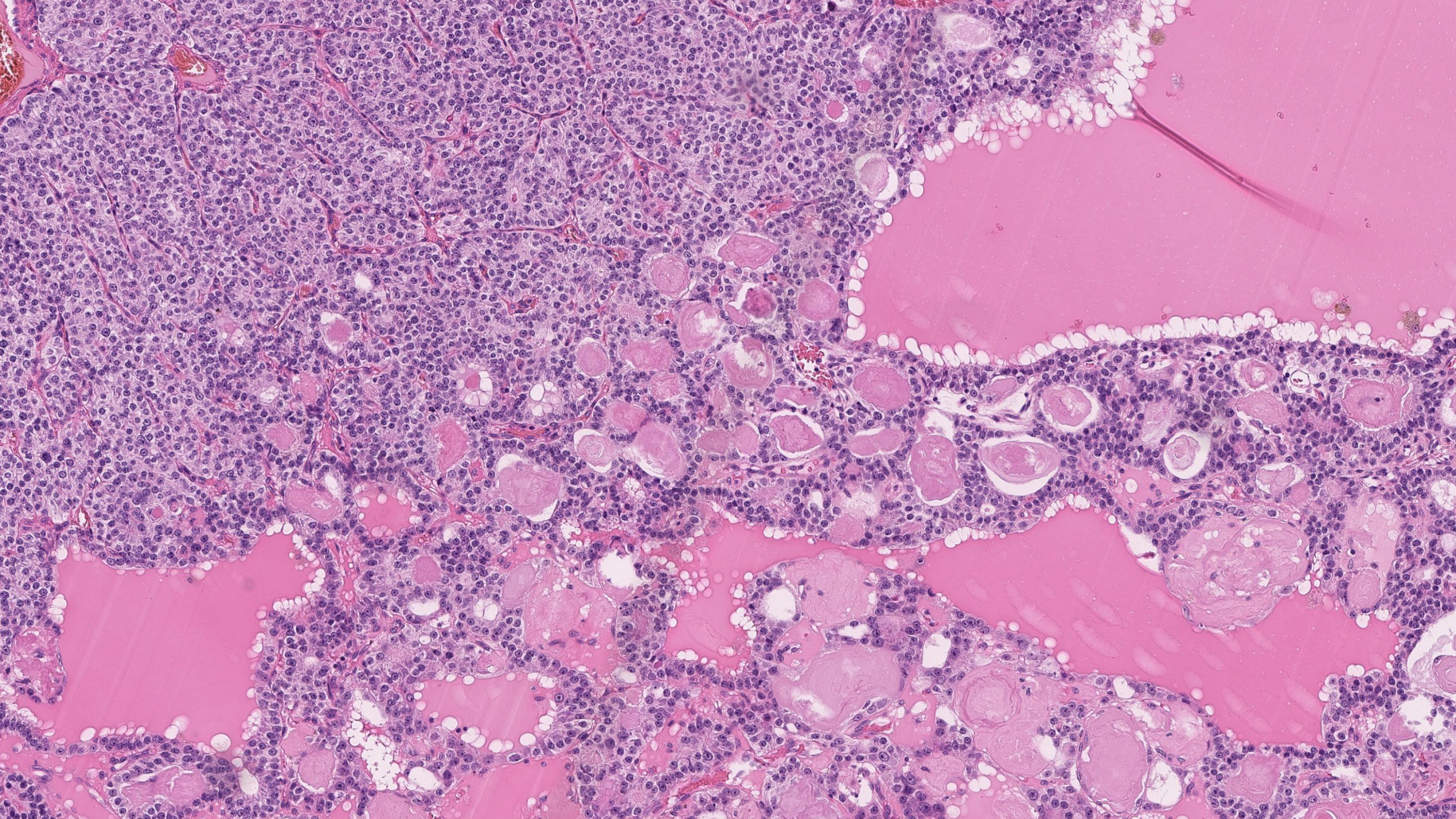
⊞

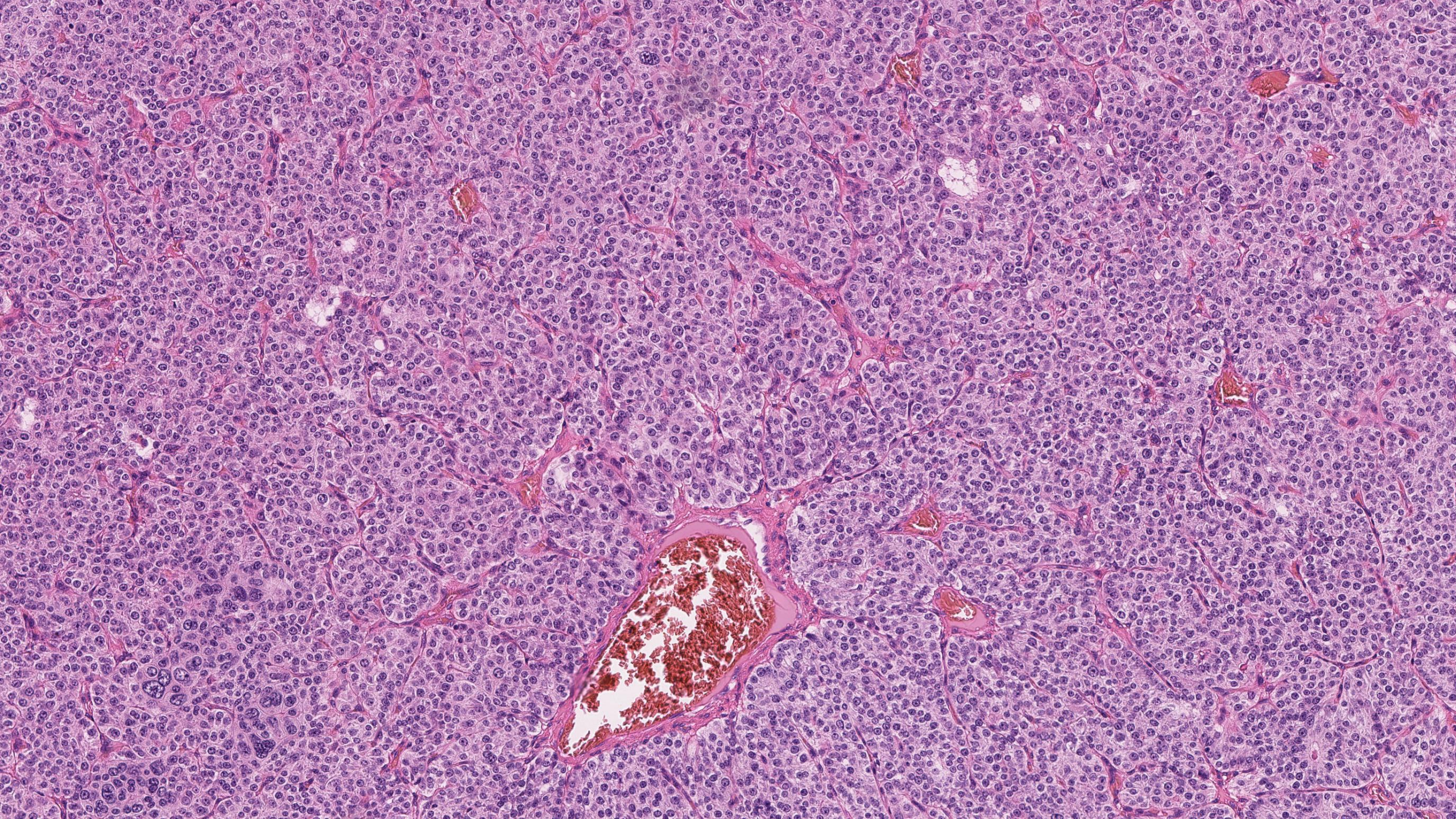


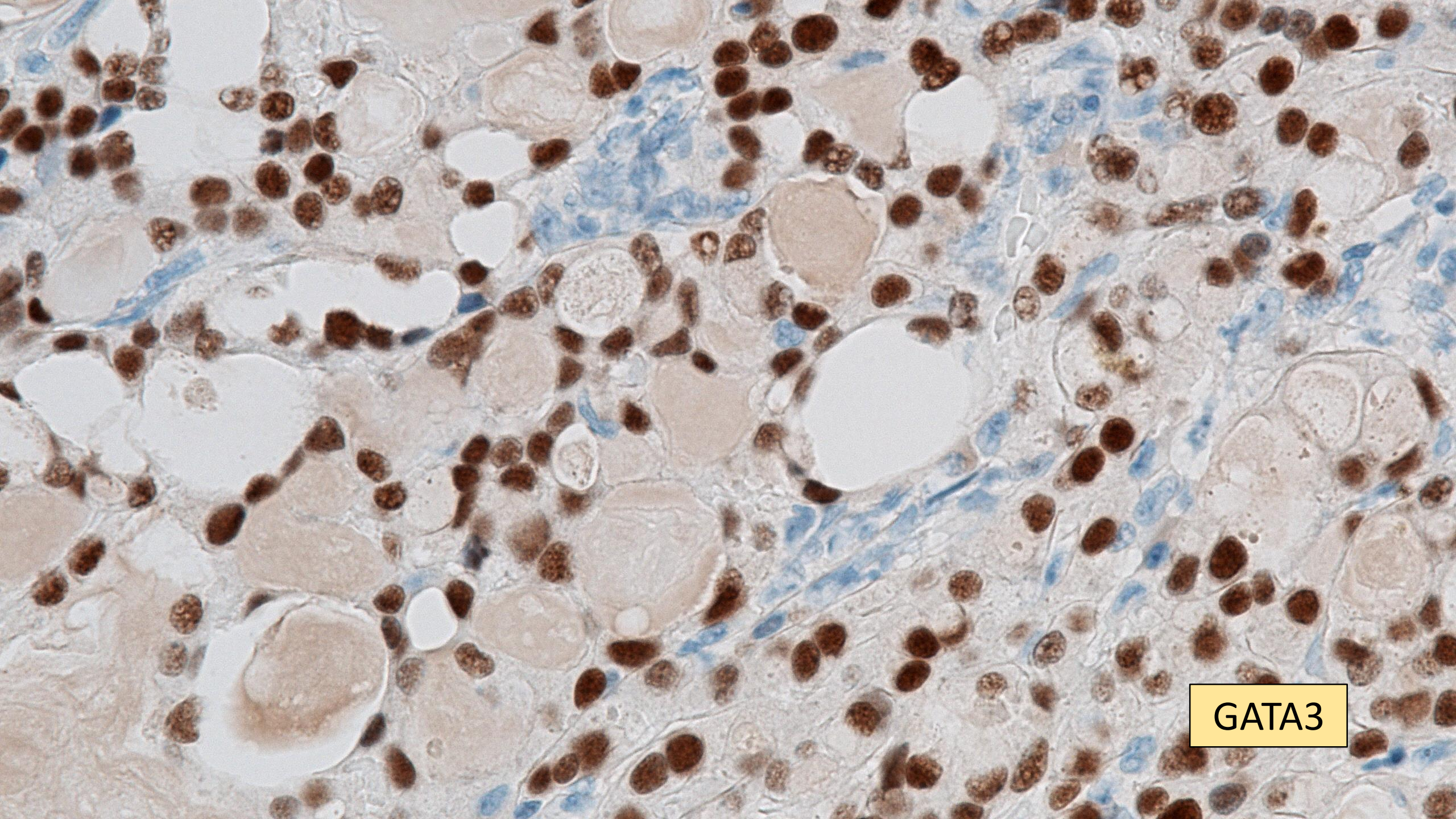












GATA3

Dg.: adenom příštítného tělíska  
s produkcí amyloidu

Nelson G. Ordoñez, M.D.

Naguib A. Samaan, M.D., Ph.D.

Michael L. Ibañez, M.D.

Robert C. Hickey, M.D.

# Immunoperoxidase study of uncommon parathyroid tumors

Report of two cases of nonfunctioning parathyroid carcinoma  
and one intrathyroid parathyroid tumor-producing amyloid

Leedham PW, Pollock DJ. Intrafollicular amyloid in primary hyperparathyroidism. *J. Clin. Pathol.* 1970; 23; 811–817.

Lieberman A, De Lellis RA. Intrafollicular amyloid in normal parathyroid glands. *Arch. Pathol.* 1973; 95; 422–423.

Anderson TJ, Ewen SWB. Amyloid in normal and pathological parathyroid glands. *J. Clin. Pathol.* 1974; 27; 656–663.

neoplasms. An intrathyroid parathyroid tumor, associated with large amounts of interstitial amyloid, mimicking medullary carcinoma of the thyroid, in a patient with primary hyperparathyroidism is also reported. Positive immunoreaction in the tumor cells for parathormone, negative staining for calcitonin, and the return of patients' serum calcium levels to normal after tumor resection, confirmed the parathyroid nature of this neoplasm. Immunohistochemistry studies proved to be extremely helpful in establishing the diagnoses of these unusual parathyroid tumors.

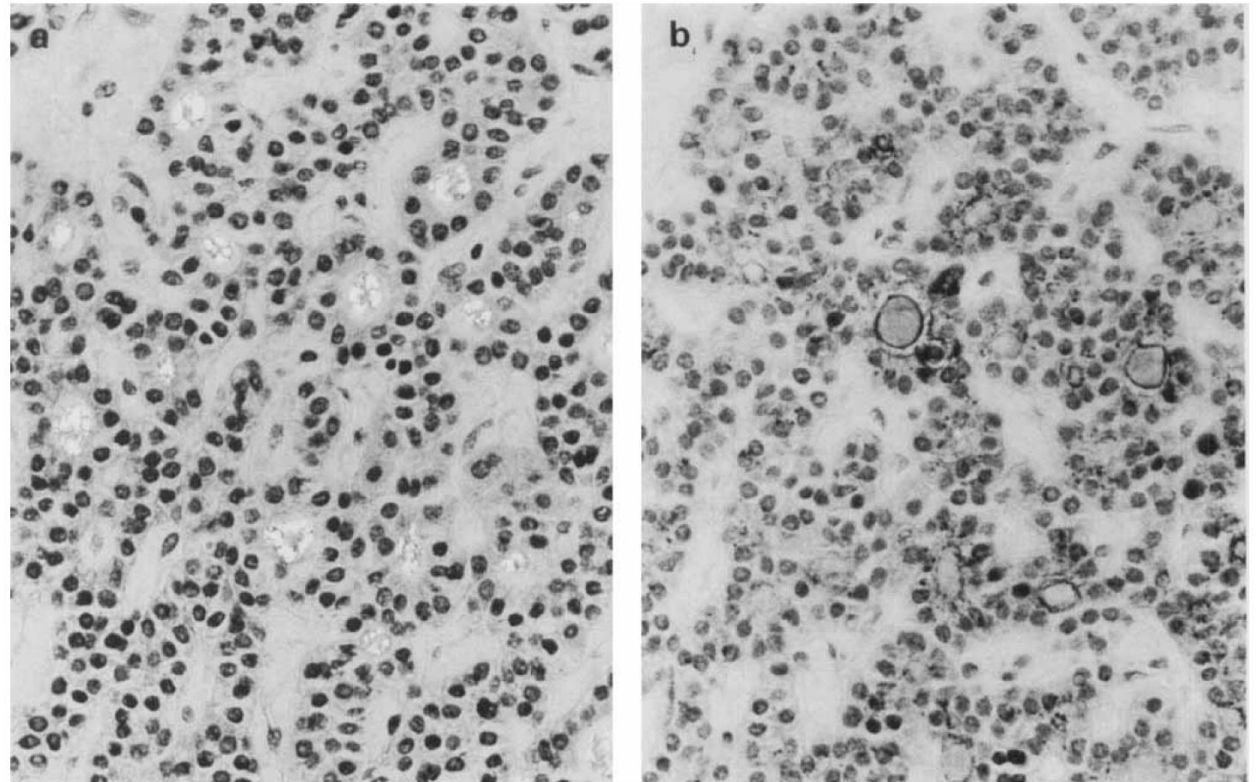
***Am J Surg Pathol 7: 535–542, 1983.***

# Parathyroid hyperplasia in multiple endocrine neoplasia type 1: a pathological and immunohistochemical reappraisal

H.R.HARACH & B.JASANI

*Department of Pathology, University of Wales College of Medicine, Cardiff, Wales*

Glandular structures showed empty lumens as well as intraluminal dense or vacuolated colloid-like material devoid of birefringent oxalate crystals (Figures 2, 3 & 5). The dense colloid-like material frequently showed the staining properties of amyloid. Intraluminal amyloid was present in 14 (58%) of 24 parathyroid glands in areas of diffuse (8/20; 40%) and nodular hyperplasia (8/16; 50%) (Figure 4). No extraluminal amyloid was identified.



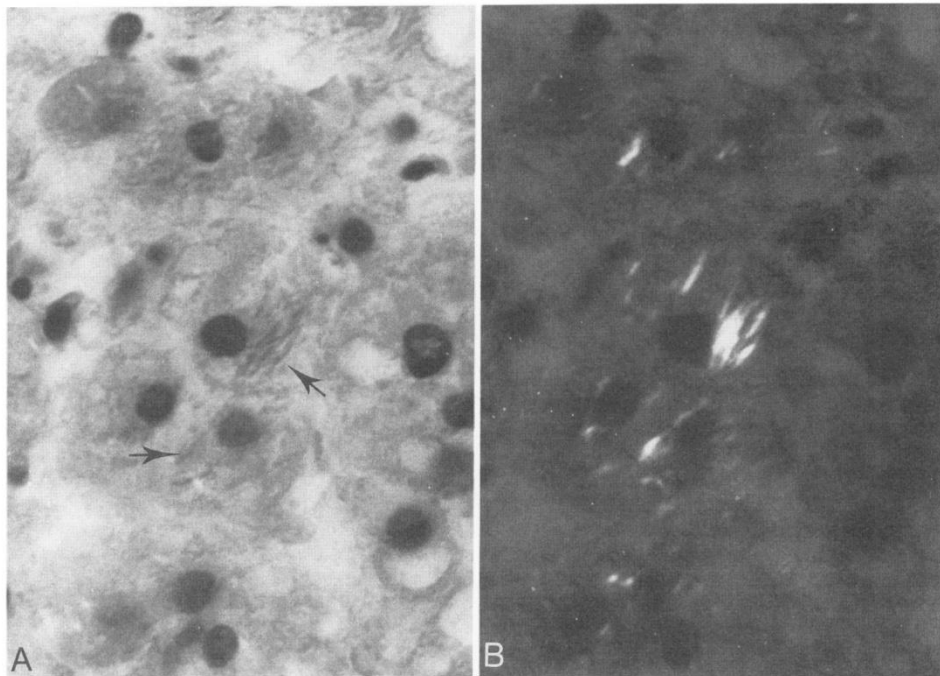
**Figure 4.** Serial sections illustrating amyloid material within glandular lumens showing a Congo red green birefringence under polarization and **b** parathyroid hormone immunostaining outlining the amyloid.



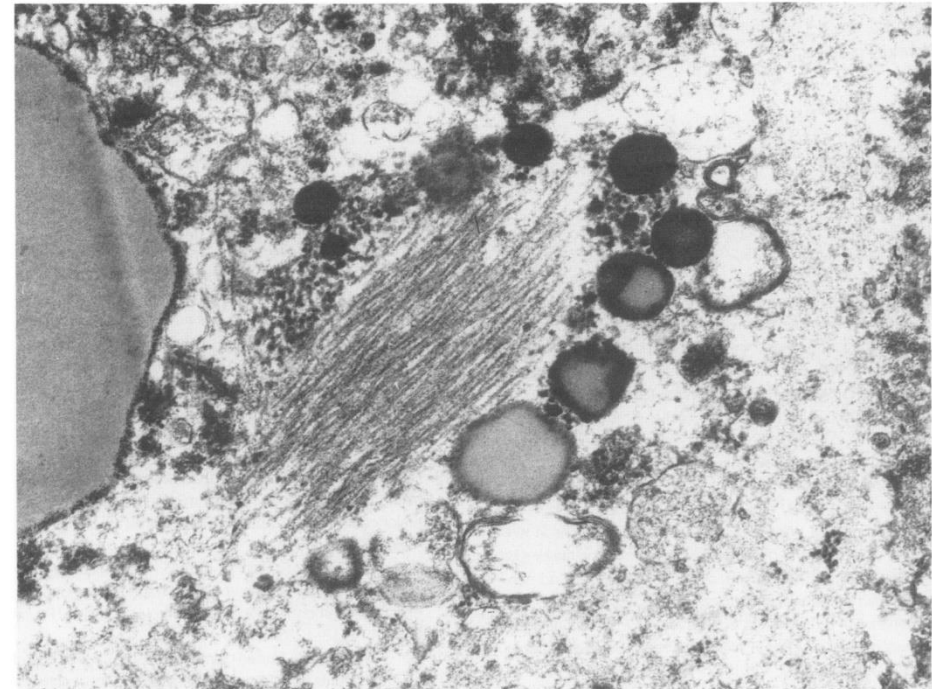
## Age-related Accumulation of Amyloid Inclusions in Adrenal Cortical Cells

**Lars Eriksson and Per Westermark\***

*From the Departments of Pathology, the University of Uppsala, Uppsala, and the Department of Pathology, University of Linköping,\* Linköping, Sweden*



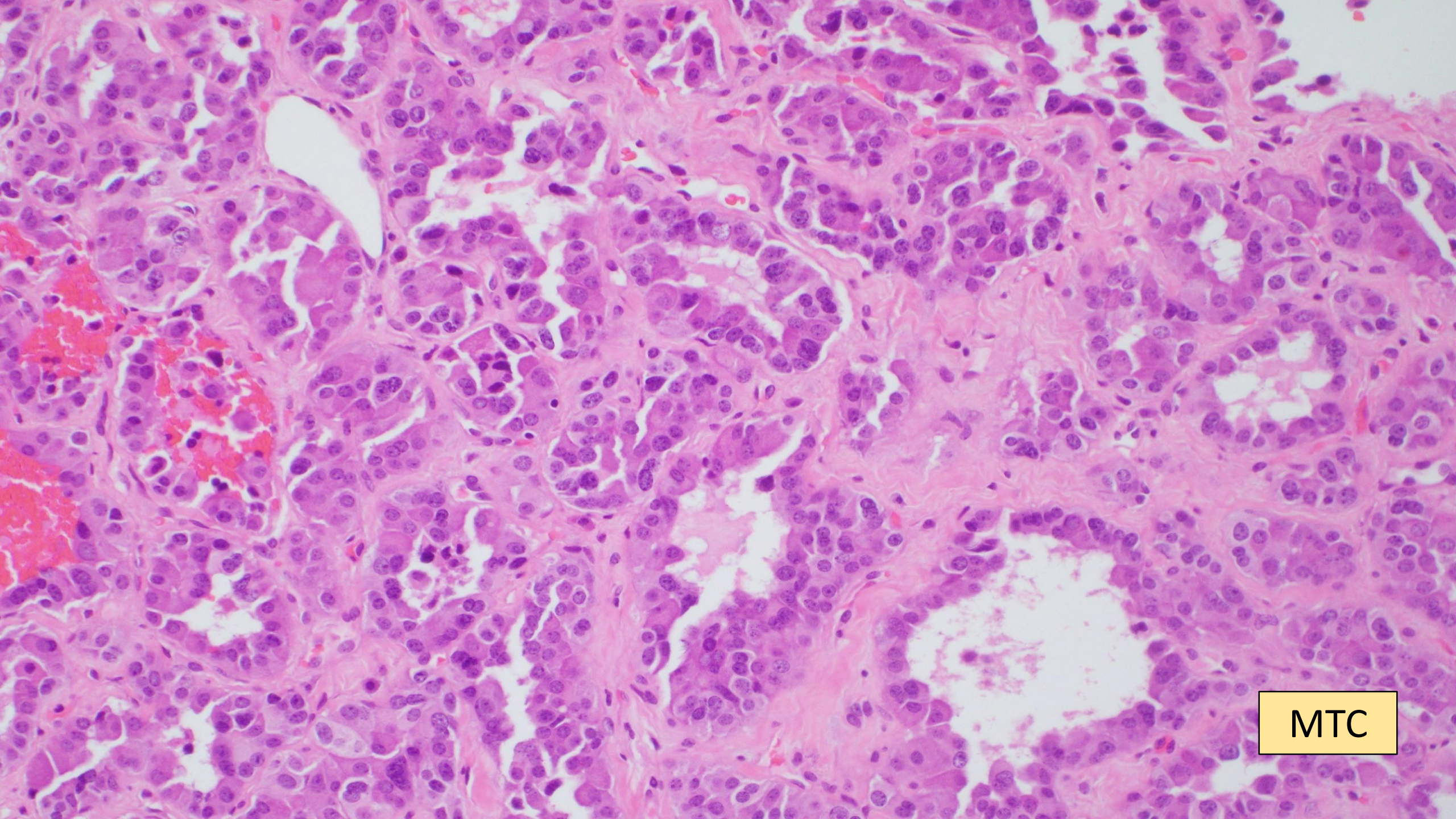
**Figure 1.** Cortical epithelial cells some of which contain many needle-shaped amyloid inclusions (arrows) showing affinity for Congo red (A) and a bright green birefringence in polarized light after such staining (B).  $\times 1200$ .



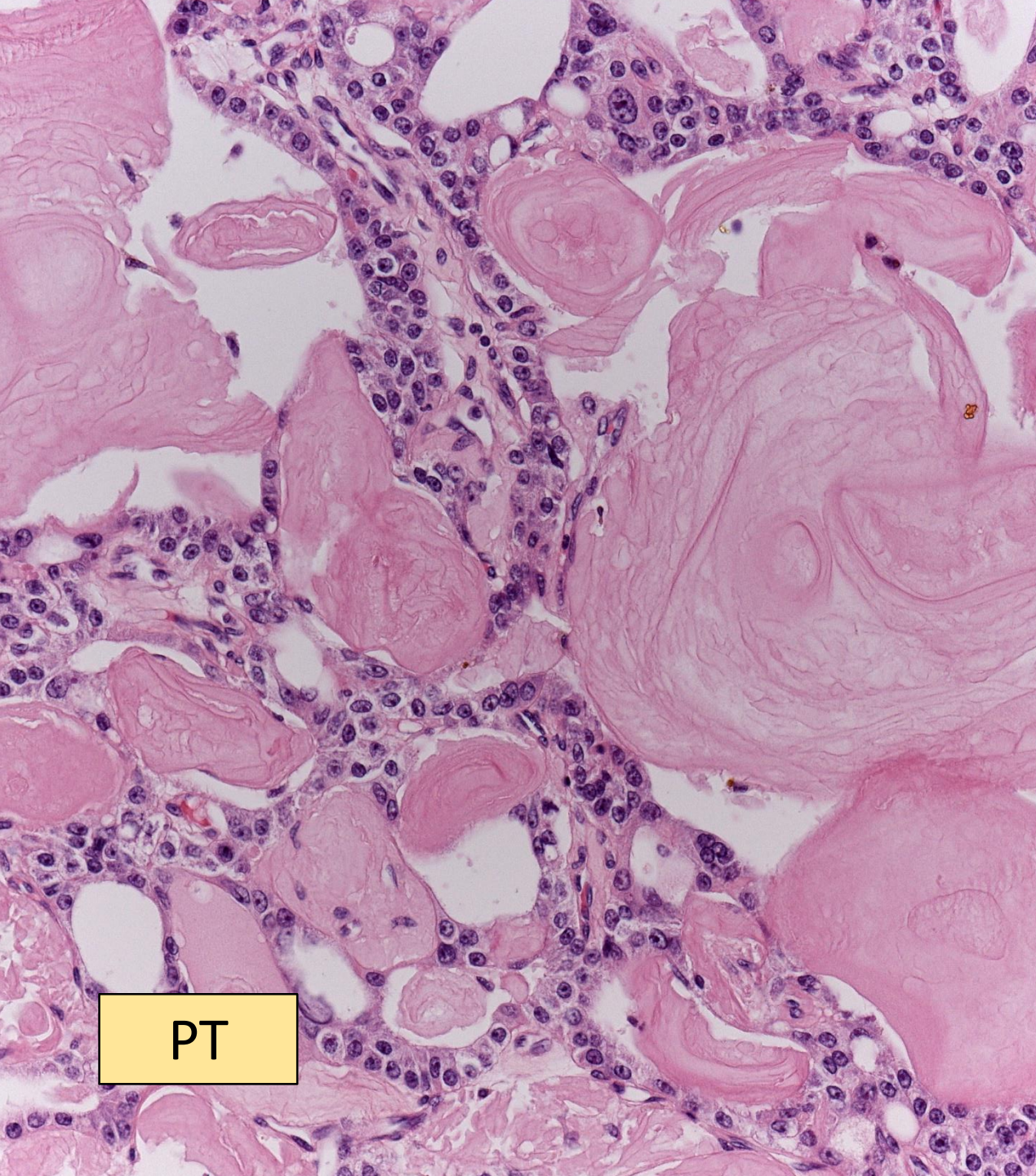
**Figure 3.** A bundle of intracellular fibrils in contact with lipid droplets.  $\times 81,000$ .

# Diferenciální diagnostika

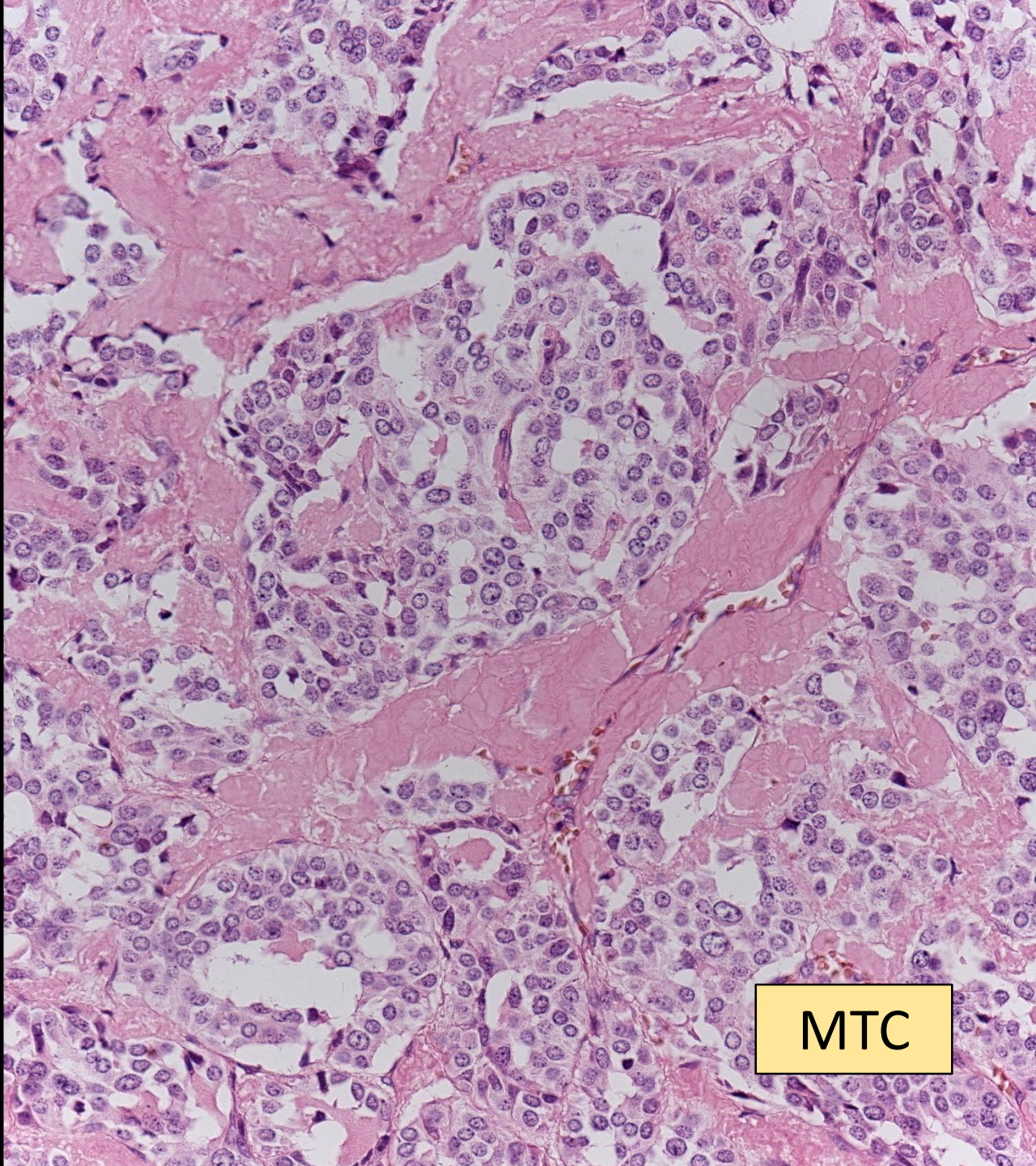
- Medulární karcinom – folikulární úprava (pattern)
- Smíšený medulárně-folikulární karcinom



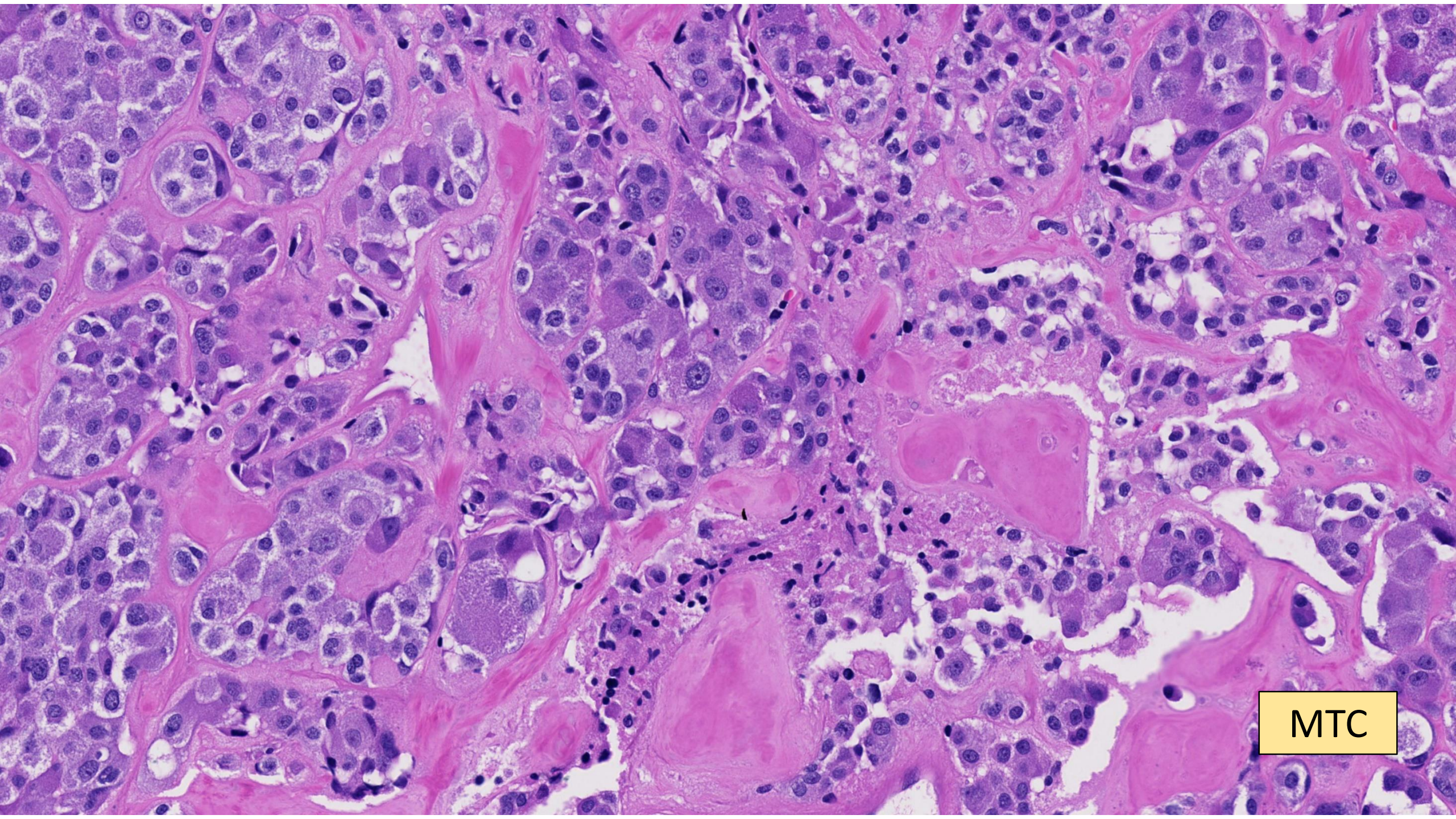
MTC



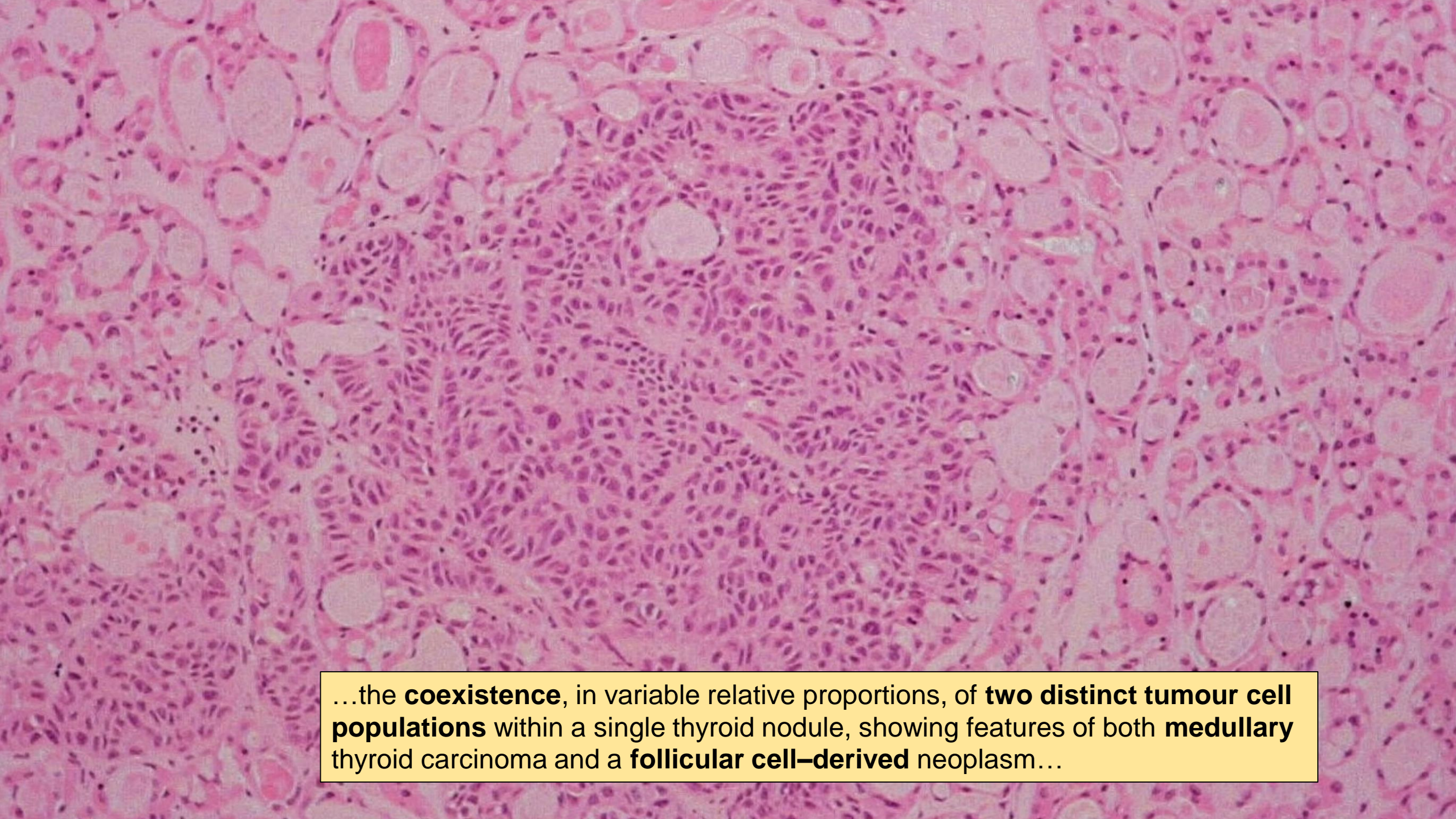
PT



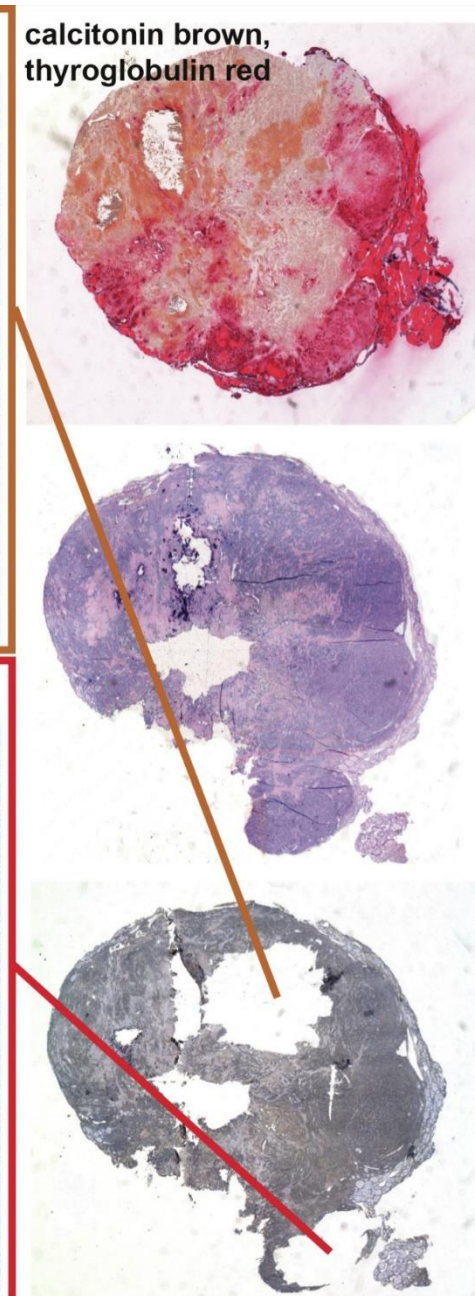
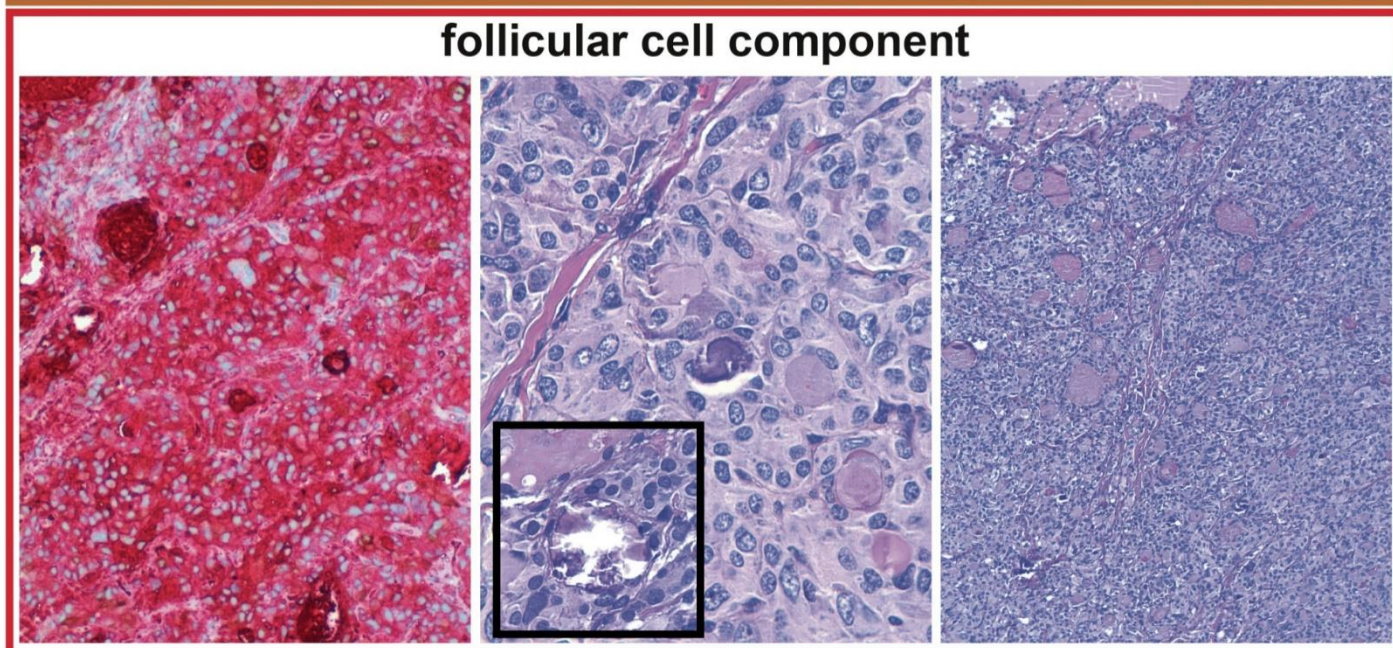
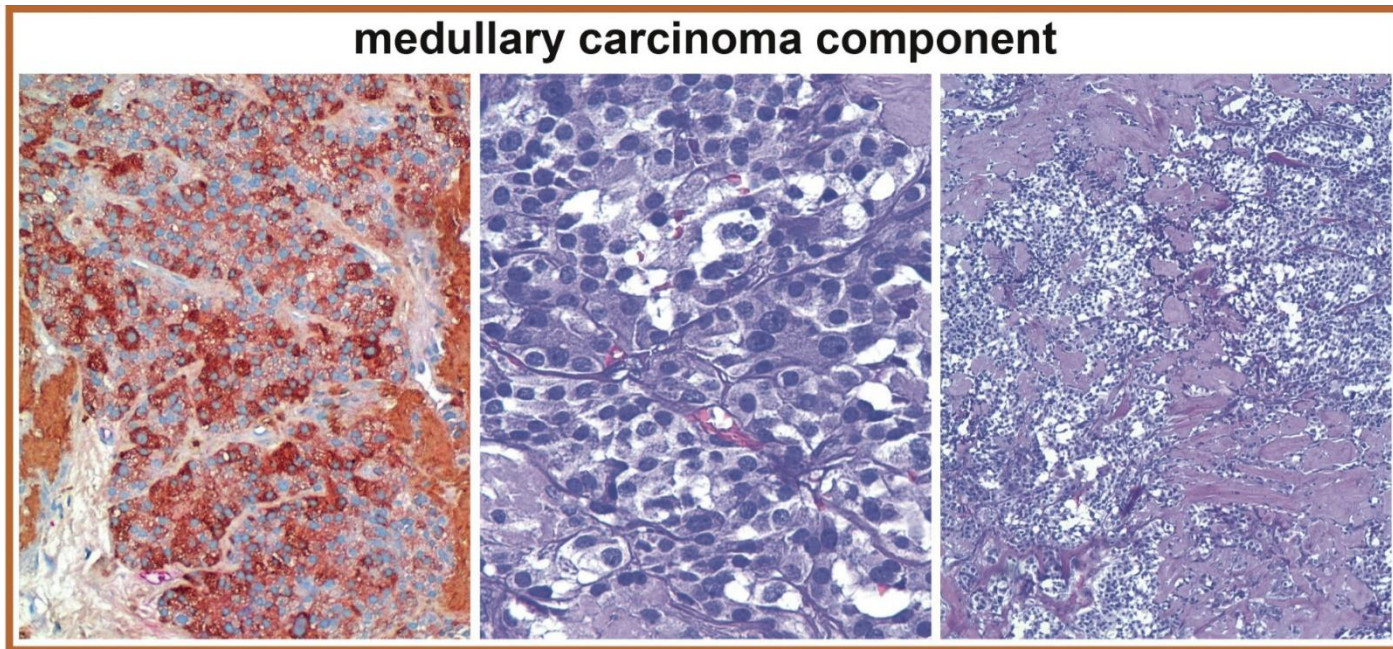
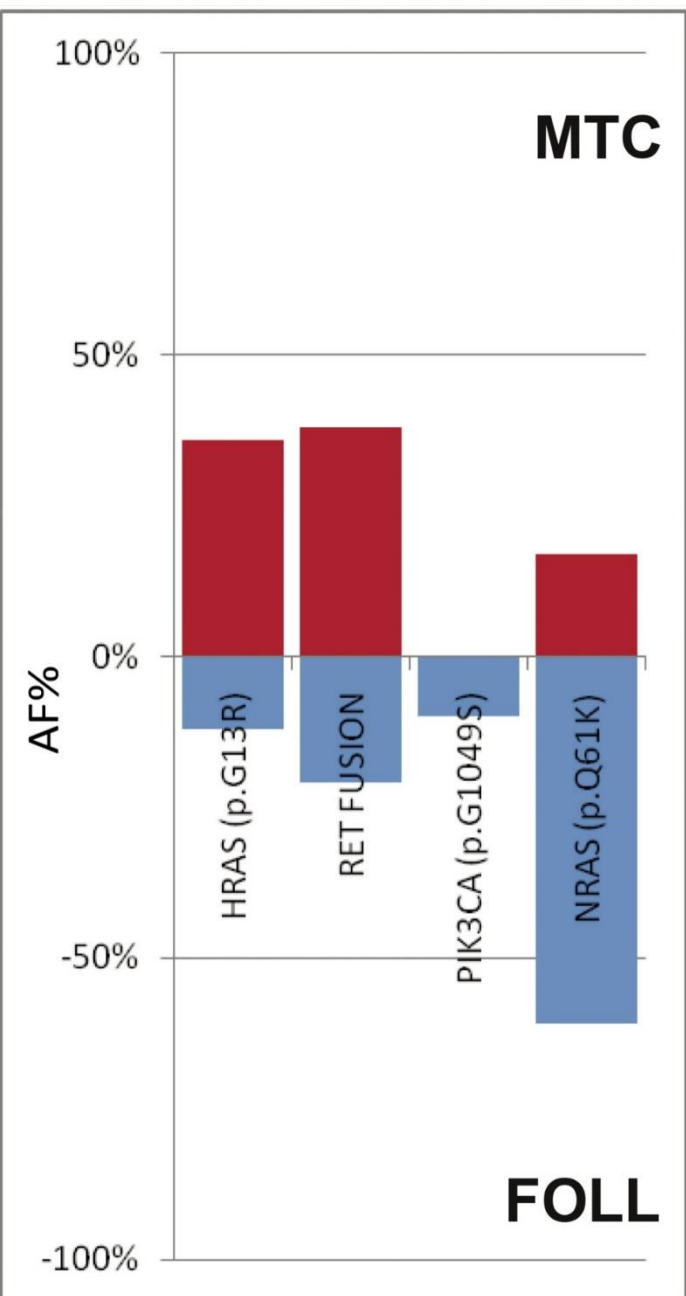
MTC

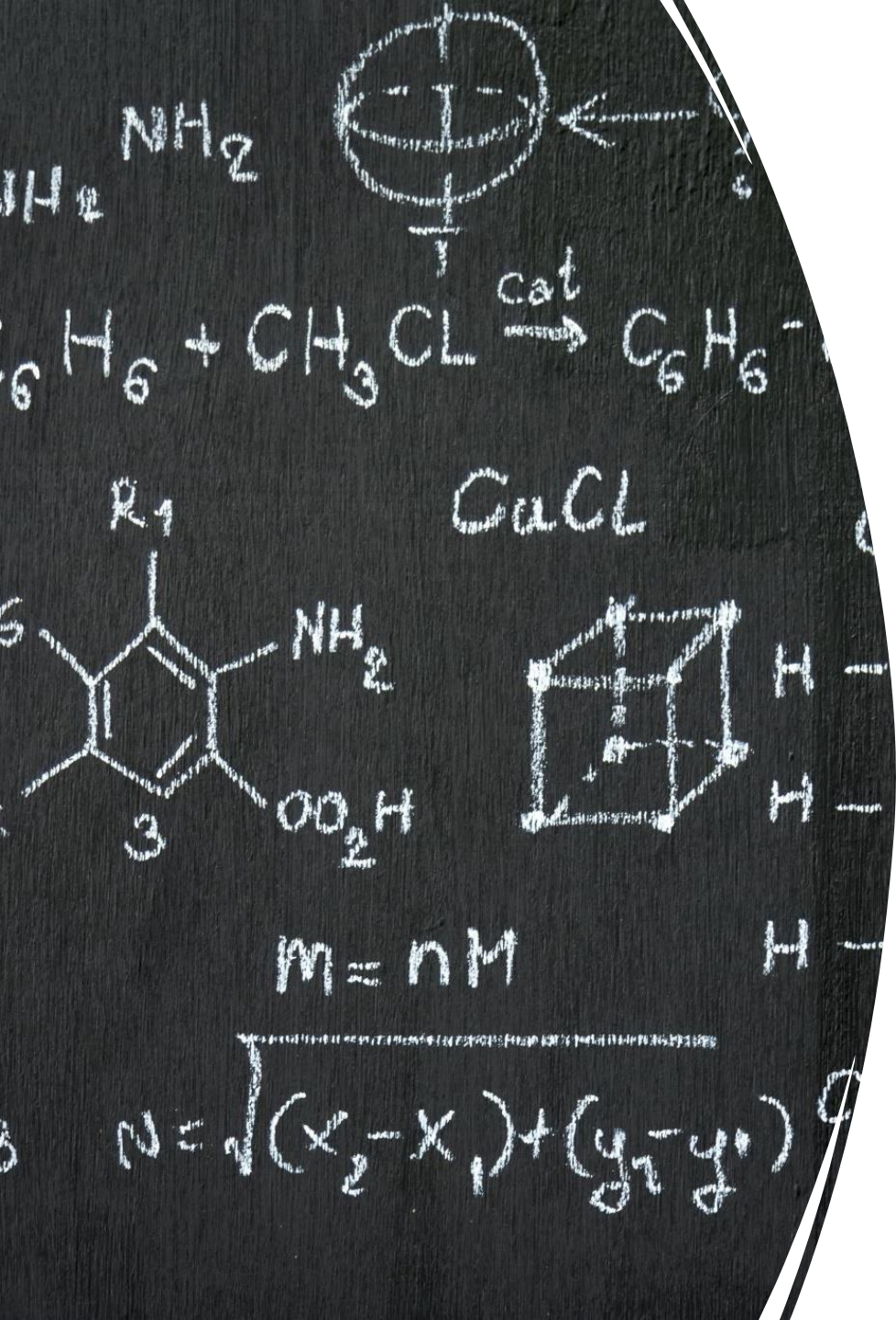


MTC

The image is a histological micrograph of a thyroid nodule stained with hematoxylin and eosin (H&E). It displays two distinct cellular populations. One population consists of cells with a characteristic 'salt and pepper' chromatin pattern, typical of medullary thyroid carcinoma. The other population consists of cells arranged in follicles, characteristic of a follicular cell-derived neoplasm. The two populations are intermingled within the same nodule, demonstrating their coexistence.

...the **coexistence**, in variable relative proportions, of **two distinct tumour cell populations** within a single thyroid nodule, showing features of both **medullary thyroid carcinoma** and a **follicular cell-derived** neoplasm...





# Take home message

---

- Adenomy i hyperplazie PT mohou být sdruženy s produkcí amyloidu
- Imunofenotyp je charakteristický
- Think outside of the box
- Klinicko-patologická korelace



